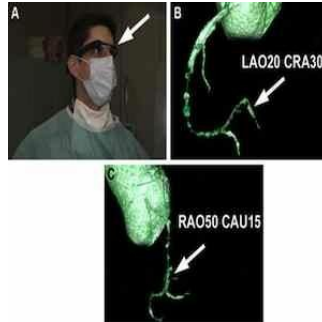


---

## Virtual Reality and The Final Frontier in Interventional Cardiology



---

Virtual reality device was successfully used to guide recanalization of right coronary artery as reported by the *Canadian Journal of Cardiology*.

Virtual reality (VR) is expected to revolutionise medicine and healthcare. Already, several medical specialties are using it to train physicians and assist diagnosis. It is believed that VR has tremendous potential for treatment as well.

See also: [Virtual Reality Meets Angiography](#)

As reported in the *Canadian Journal of Cardiology*, a group of cardiologists used a VR device to guide revascularisation of a chronically blocked right coronary artery. The condition is often referred to as the "final frontier in interventional cardiology" as it has unpredictable procedural success rates and is considered to be a major challenge for PCI.

Cardiologists from the Institute of Cardiology, Warsaw, Poland were able to restore blood flow in the occluded right coronary artery of a 49-year-old male patient by using CTA projections in a wearable VR device based on Google Glass. The three dimensional CT reconstructions were equipped with a hands-free voice recognition system as well as a zoom function. This enabled the team to visualise the distal coronary vessel and verify the direction of the guide wire advancement relative to the course of the blocked vessel segment. The procedure was completed successfully with implantation of two drug-eluting stents.

"This case demonstrates the novel application of wearable devices for display of CTA data sets in the catheterisation laboratory that can be used for better planning and guidance of interventional procedures, and provides proof of concept that wearable devices can improve operator comfort and procedure efficiency in interventional cardiology," explained lead investigator Maksymilian P. Opolski, MD, PhD, of the Department of Interventional Cardiology and Angiology at the Institute of Cardiology, Warsaw, Poland.

Source: [Canadian Journal of Cardiology](#)

Image Credit: Institute of Cardiology, Warsaw, Poland

Published on : Tue, 24 Nov 2015