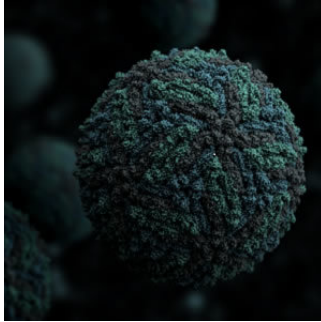


## RSNA Report: Imaging Zika Virus



---

The Radiological Society of North American (RSNA) has released a report that details the spectrum of imaging findings in babies and fetuses infected with the Zika virus. The report is published in *Radiology*.

The report presents several ultrasound, MRI and CT images of Zika virus during pre- and postnatal development. The images show the profound effects of the disease.

The report's lead author Fernanda Tovar-Moll, MD, PhD, vice president of the D'Or Institute for Research and Education and professor at the Federal University of Rio de Janeiro, Brazil explains that imaging is critical for identifying the presence and severity of the structural changes caused by the infection.

The Zika virus is most dangerous when passed on from a pregnant mother to her fetus during the first trimester. The chances of brain defects in the baby, including microcephaly increases and the virus can also result in eye defects, hearing impairment and stunted growth in babies. As pointed out by coauthor Deborah Levine, M.D., director of obstetric and gynecologic ultrasound at Beth Israel Deaconess Medical Center and professor of radiology at Harvard Medical School in Boston, from an imaging standpoint, the abnormalities in the brain are very severe with Zika as compared to other congenital infections.

A retrospective review of imaging and autopsy findings of congenital Zika virus infection was performed in the Instituto de Pesquisa in Campina Grande state Paraiba (IPESQ) in northeastern Brazil. From a group of 438 patients, the researchers identified 17 fetuses or neonates of women who had imaging at IPESQ and confirmed Zika infection and 28 neonates with brain findings suspicious for Zika infection. The imaging exams that were conducted include fetal MRI, postnatal brain CT, postnatal brain MRI and, in some cases, longitudinal prenatal ultrasound.

The images show a variety of abnormalities in fetuses that had been exposed to the virus including gray and white matter volume loss, brainstem abnormalities, calcifications and ventriculomegaly. Brain abnormalities observed in the confirmed and presumed Zika groups were quite similar. Most of the babies had ventriculomegaly. 94 percent of the babies in the confirmed Zika group and 79 percent in the presumed Zika group had abnormalities of the corpus callosum, All babies except one had cortical migrational abnormalities. Almost all the neonates had intracranial calcifications and exhibited reduced tissue volume in the brain. Most patients showed abnormalities in cortical development.

"The severity of the cortical malformation and associated tissue changes, and the localisation of the calcifications at the grey-white matter junction were the most surprising findings in our research," Tovar-Moll said.

Source: [RSNA](#)  
Image Credit: Wikimedia Commons

Published on : Tue, 6 Sep 2016