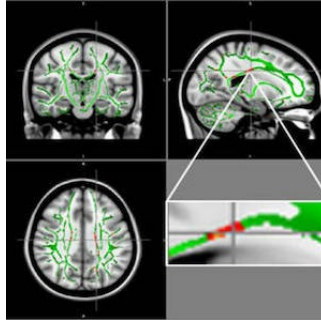


---

## RSNA 2019: MRI Reveals Brain Damage in Obese Teens



---

An imaging study reveals obesity amongst young people may be due to brain changes that affect important regions responsible for control of appetite and emotions.

There is a pattern of brain damage which, according to researchers, has to do with some inflammatory markers like leptin, a hormone made by fat cells that helps regulate energy levels and fat stores. Leptin resistance occurs when the brain stops responding to leptin, causing obese people to keep eating despite adequate or excessive fat stores.

A study on the topic is being presented next week in Chicago at the annual meeting of the Radiological Society of North America (RSNA).

Diffusion tensor imaging (DTI), an MRI technique that tracks the diffusion of water along the brain's signal-carrying white matter tracts, has made it possible for the researchers to investigate this kind of damage in the brains of obese adolescents.

The current study compared DTI results in 59 obese adolescents and 61 healthy adolescents, between the ages 12 and 16 years. From DTI, the researchers derived a measure called fractional anisotropy (FA), which correlates with the condition of the brain's white matter. A low FA indicates there is damage in the white matter.

The researchers reported these key findings:

- Obese group showed reduced FA values in regions located in the corpus callosum, a bundle of nerve fibres that connects the left and right hemispheres of the brain;
- FA decline was also found in the middle orbitofrontal gyrus, a brain region related to emotional control and the reward circuit; and
- Worsening condition of the white matter was also associated with levels of insulin, a hormone produced in the pancreas that helps regulate blood sugar levels.

"Our maps showed a positive correlation between brain changes and hormones such as leptin and insulin," said study co-author Pamela Bertolazzi, a biomedical scientist and PhD student from the University of São Paulo in Brazil.

Study results also suggest a positive association with inflammatory markers, "which leads us to believe in a process of neuroinflammation besides insulin and leptin resistance," Dr Bertolazzi added. However, further studies are needed to determine if this type of inflammation in young people with obesity is a consequence of the structural changes in the brain.

"In the future, we would like to repeat brain MRI in these adolescents after multiprofessional treatment for weight loss to assess if the brain changes are reversible or not," Dr Bertolazzi pointed out.

Obesity in adolescents is now a major public health problem. In the U.S. alone, the number of children and adolescents who are obese has more than tripled since the 1970s, according to the Centers for Disease Control and Prevention.

Source: Radiological Society of North America  
Image credit: Pamela Bertolazzi, Ph.D.

Published on : Mon, 25 Nov 2019