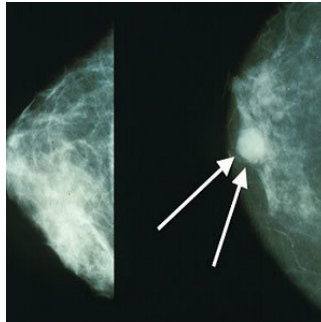


Radiologists Can Detect Breast Cancer in 'Blink of an Eye'



A study conducted by investigators at Brigham and Women's Hospital, the University of York in the UK and MD Andersen Cancer Center in Texas tests the ability of experienced radiologists' to sense when a mammogram is abnormal. The paper is published in the *Proceedings of the National Academy of Sciences*.

For the purpose of the investigation, visual attention researchers showed mammograms to radiologists for half a second and found that they could identify abnormal mammograms at better than chance levels. The ability was further tested through a series of experiments in order to determine what signal alerts radiologists to the presence of an abnormality.

Jeremy Wolfe, PhD, senior author of the study and director of the Visual Attention Laboratory at BWH explains that radiologists have hunches when they look at a mammogram and these hunches are based on something real that they see on the images. Their expertise enables them to pick up on an abnormality in the blink of an eye. They can even detect something abnormal in the other breast that does not contain a lesion.

While in the clinic, an image is never really assessed in half a second but the point is that these experts have the ability to extract the gist of an image very quickly. In a previous study, Wolfe and his colleagues found that radiologists could detect abnormal mammograms after a half-second glimpse but non-experts could not do the same. In this new study, the researchers tested whether breast tissue symmetry, breast density, image size, resolution or other characteristics were contributing factors to the success rate of the radiologists.

Findings show that performance is not dependent on breast symmetry or breast density but on other finer details related to the texture of the breast tissue. However, the study shows that radiologists can do better than chance in discriminating breast cancer cases from normal tissue, even when the images of abnormal breast tissue did not directly capture a cancerous lesion or when those images were taken from the contralateral breast.

"These results suggest that there may be something in the nominally normal breast that looks abnormal and is detectable," said Wolfe. "Together, these results suggest that radiologists may be picking up on some sort of early, global signal of abnormality that is unknown to us at this point."

Source: Brigham and Women's Hospital
Image Credit: Wikimedia Commons

Published on : Tue, 30 Aug 2016