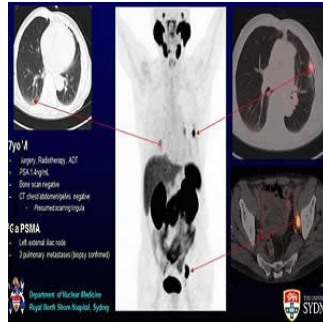


Prostate PET/CT Targets More Cancer, Improves Care



According to new research presented at the 2017 Annual Meeting of the Society of Nuclear Medicine and Molecular Imaging (SNMMI), prostate-specific molecular imaging could improve clinical management, especially in patients whose cancer returns.

The study includes data from four Australian medical centres and several hundred patients who were examined over a period of 18 months. All study patients underwent PET/CT with an injected imaging agent comprised of a tiny amount of gallium-68 (Ga-68) and prostate specific membrane antigen (PSMA). The imaging agent zeroes in on areas where the PSMA protein is over-expressed on cell surfaces. The PSMA over-expression emits a signal that is picked up by the PET scanner enabling it to create a more accurate map of the disease.

Findings showed that prostate-specific molecular imaging led to the detection of cancer that was not caught by other conventional imaging methods. Prostate-specific PET/CT was able to change the course of treatment plans for 51% of patients.

Paul J. Roach, MBBS, head of the Department of Nuclear Medicine at Royal North Shore Hospital in Sydney, Australia believes that prostate-specific PET/CT could be a game changer as it offers substantial improvement over conventional imaging for the staging of prostate cancer. Change in clinical management was especially significant in patients who showed signs of recurrent disease which was around 61% of all treatment plans including 69% for those who had received radiation therapy and 64% for those who had undergone surgery. Compared to this, conventional imaging was unable to detect disease in nearby lymph nodes in 39% of patients, in the prostate bed in 27 percent of patients, and in regions where the cancer had metastasised, in 16 percent of patients. Change in clinical management occurred in only 23% of cases.

"This is likely to become the primary imaging test for many patients with prostate cancer and will replace conventional imaging in many cases," noted Roach. "Given the prevalence of prostate cancer, this could lead to a significant increase in referrals to nuclear medicine and PET centres for Ga-68 PSMA PET/CT imaging worldwide."

Source: [Society of Nuclear Medicine](#)

Image Credit: Department of Nuclear Medicine, Royal North Shore Hospital, Sydney

Published on : Tue, 20 Jun 2017