

---

## Volume 4 - Issue 2 , 2010 - Cover Story: Cardiovascular Intervention

### Intravascular Ultrasound Imaging: Clinical & Research Applications

---

In the early stages of formation of atheroma, the remodeling of the vessel wall usually prevents plaque from encroaching on the lumen, thereby masking the presence of atheroma on angiography. In contrast, grayscale intravascular ultrasound (IVUS) can fully assess the extension of the disease axially and longitudinally. Thus, intravascular imaging has played a vital role in advancing our understanding of the pathophysiology of coronary artery disease, and in the development of novel cardiovascular drugs and device therapies. Intravascular imaging technology and its clinical and research applications are discussed in greater detail below.

#### Characterisation of Atherosclerosis

Firstly, let's examine a normal coronary artery structure, in order to differentiate its pathological conditions. The arterial wall of coronary arteries is composed of three layers. The innermost tunica intima is in direct contact with the blood and is constituted by an endothelial cell monolayer, resting on a basement membrane. Aging in human arteries is associated with the presence of smooth muscle cells in the tunica intima. These cells produce extracellular matrix molecules leading to intimal layer thickening. This process is not necessarily associated with pathological lipid accumulation and atherosclerosis formation.

The second layer, tunica media, is separated from the tunica intima by the internal elastic membrane (IEM) and is formed by concentric layers of smooth muscle cells. The adventitia is the outermost arterial layer, which is separated from the media by the external elastic membrane (EEM) and contains fibroblasts and mast cells, collagen fibrils, vasa vasorum and nerve endings.

The normal coronary architecture can be assessed using intravascular imaging. The circulating blood elements may assist IVUS image interpretation and differentiate lumen from vessel wall, as these produce characteristic speckles in the image. However, blood speckles are dependent on flow velocity and may have increased intensity in the case of slow blood flow, which may have a similar appearance to the vessel wall. The reported normal value for intimal thickness in young subjects is typically  $0.15 \pm 0.07$  mm. Thus, a thin tunica intima reflects ultrasound poorly and is not visualised as a separate layer.

The media is typically less echogenic than the intima, but may appear thick because of signal attenuation and weak reflectivity of the internal elastic membrane. A monolayer appearance is a common finding in normal coronary arteries, while a trilayered appearance suggests the presence of intimal thickening. A trilaminar appearance is dependent not only on the age but also on the histologic characteristics of the vessel. The adventitia has the strongest echo signal, which is used as a reference to determine plaque components. Importantly, the IVUS beam penetrates beyond the adventitial layer allowing visualisation of perivascular structures, including the cardiac veins and the pericardium. Based on histologic and ultrasound data, coronary vessel walls with an intimal thickness of  $\geq 0.5$  mm are considered to be diseased.

#### Clinical Applications: Diagnostic Severity and Extent of Atherosclerosis

Determination of the severity and extent of atherosclerosis remains one of the main diagnostic clinical applications of intravascular imaging, as angiography and non-invasive methods lack sufficient spatial or temporal resolution for accurate coronary disease assessment. Standards for acquisition, measurement and reporting of IVUS have been proposed in clinical expert consensus documents. Luminal area stenosis describes the relative decrease in luminal cross-sectional area (CSA) at the site of disease, in percentage, compared to lumen CSA in a "normal appearing" reference segment in the same coronary.

The lumen area relative to the reference lumen area is analogous to the angiographic definition of diameter stenosis. Proximal and distal reference lumen areas are calculated at sites with the largest lumen located prior to large side branches and within 10 mm proximal and distal to the plaque, respectively. The image analyst should be aware of potential post stenotic dilatation of the vessel wall when using these measurements to guide clinical decision-making. Minimal lumen area (MLA) describes the smallest lumen CSA area along the length of the target lesion.

As most vessels depict an oval rather than a perfect circular shape, maximum and minimal lumen diameters are calculated along a vector passing through the lumen centre at the reference segments. Calculation of reference vessel lumen diameter is essential in order to guide selection of interventional devices. Measurements of distances (length) are based on the automated pullback speed during image acquisition. Disease length can be calculated based on number of seconds or frames between the first and last image frames depicting the atherosclerotic plaque.

#### Assessment of Atheroma Burden

Quantification of atheroma or plaque area in cross-sectional IVUS images is performed by subtracting the lumen area from the external elastic lamina (EEL) area or vessel area. (see figure 1). Hence, the IVUS-defined atheroma area is a combination of plaque plus media area. The atheroma area can be calculated in each frame (cross-sectional image), and total atheroma volume (TAV) can be calculated based on pullback speed during imaging acquisition. Atheroma volume can be reported as the percentage of the volume of the external elastic membrane occupied by atheroma, namely percent atheroma volume (PAV). Measurements are performed between the inner lumen border and the media, delimited by the IEL, which corresponds to the "true" histological area of the atheroma.

#### Drug Effects on Atherosclerosis

The initial observations about a positive continuous relationship between coronary heart disease risk and blood cholesterol levels led to the conduction of a number of IVUS-based studies to evaluate the effect of different lipid lowering drugs on atheroma size. Changes in plaque characteristics may be a more relevant endpoint to predict risk of vascular thrombosis than plaque progression or regression of mild to moderate

disease, but imaging tools to accurately evaluate plaque characteristics were not available until recently. Other limitations of using conventional grayscale IVUS to assess the natural history of atherosclerosis should be enumerated:

1. Catheterisation, which is an invasive procedure, is required for serial imaging;
2. Only a segment of the coronary tree can be studied;
3. Plaque composition is not obtained, and
4. There is no direct evidence linking changes in coronary plaques and clinical events.

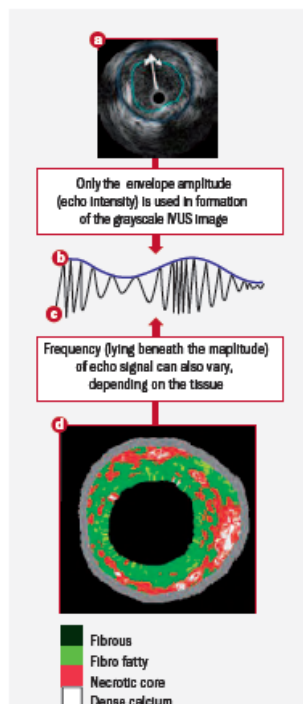
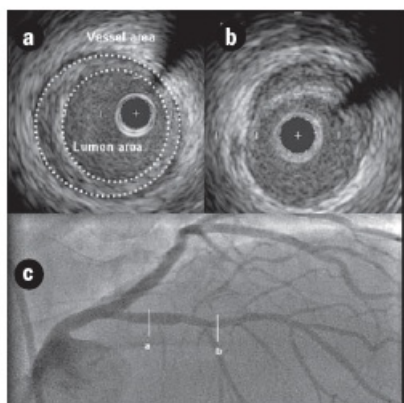
More recently, autoregressive spectral analysis of IVUS backscattered data has been incorporated into conventional IVUS systems to facilitate image interpretation of different tissue components (i.e. necrotic core in red, dense calcium in white, fibrous in dark green, and fibro-fatty in light green) (see figure 2).

### Restenosis

Unlike restenosis after balloon angioplasty or atherectomy, IVUS studies have shown that in-stent restenosis is essentially a result of neointimal hyperplasia. Predictors of stent restenosis have been identified by multivariate analyses and include small reference vessel and lumen size, the larger plaque burden, and small in-stent lumen area. While the prevalence of restenosis has decreased dramatically with DES, maximising luminal gain remains an important approach to prevent restenosis. Receiver operating characteristic curve identified post-stenting minimum stent CSA of 5 mm<sup>2</sup> for sirolimus-eluting stent and 6.5 mm<sup>2</sup> for bare metal stents were associated with lumen CSA > 4-mm<sup>2</sup> at 8-months follow-up. Others have shown that the highest restenosis rate was observed in lesions with stent area <5.5 mm<sup>2</sup> and stent length >40 mm after deployment of sirolimus-eluting stents.

**Figure 2.** Intravascular ultrasound signal is obtained from the vessel wall (a). Grayscale IVUS imaging is formed by the envelope (amplitude) (b) of the radiofrequency signal (c). Panel a shows a cross-sectional view of a grayscale image. The blue lines limit the actual atheroma. The frequency and power of the signal commonly differ between tissues, regardless of similarities in the amplitude. From the backscatter radiofrequency data virtual histology can be retrieved (panel d).

**Figure 1.** This figure illustrates the heterogeneity nature of the atherosclerosis disease and the lack of correlation of IVUS findings (panels a and b) and angiography appearance (panel c). Patient presented with stable angina due to a significant lesion in the right coronary artery which was stented (not shown). A grayscale IVUS pull-back in the left anterior descending (LAD) was performed in order to better characterise the mild lesion present in its mid segment. Panel a shows a concentric plaque in the proximal part of the LAD that angiographically has minimum lumen compromise. Panel b depicts a soft eccentric plaque in the mid LAD.



In addition, while diffuse in-stent restenosis is common after bare metal stents, the pattern of restenosis associated with DES is most frequently focal. One of the most common variables used to report restenosis is percentage intimal hyperplasia volume in the stent segment (see figure 3). This variable normalises the intimal hyperplasia to the stent length therefore allowing the comparison of different stent types (BMS vs. DES), as well as different drug types (i.e. SES vs. PES). The percentage intimal hyperplasia, however, minimises the impact of focal restenosis.

A meta-analysis of TAXUS IV, V and VI demonstrated that nearly half of the stent length was free of IH in the TAXUS group ( $48.8 \pm 36.0\%$  vs.  $13.4 \pm 22.1\%$  in the control group,  $p < 0.0001$ ). In another study comparing the paclitaxel stent and sirolimus stent, 46.1 vs. 5.4% of the stent length had covering,  $p < 0.001$ , respectively. A similar intimal hyperplasia distribution to the TAXUS stent has been reported for the zotarolimus-eluting stent. It has been suggested that the "patchy" distribution of intimal growth associated with DES (i.e. lack of neointimal tissue in the mid portion of the stent) could be related to a higher concentration of drug in that portion of the stent.

### Clinical Applications: Interventional

The utilisation of intravascular imaging to guide percutaneous coronary interventions (PCI) is heterogeneously distributed across the world, varying from > 60 percent of use during PCI in Japan to less than 20 percent in Europe and the United States. The explanation for such disparity is multi-factorial but likely involves local reimbursement practices for the procedure, differences in clinical practice and training, and a relative lack of scientific evidence.

### Pre-Interventional Imaging

© For personal and private use only. Reproduction must be permitted by the copyright holder. Email to [copyright@mindbyte.eu](mailto:copyright@mindbyte.eu).

Intravascular imaging provides the only means to accurately determine vessel size, severity, character, extent, and location of disease and to guide therapeutic decisionmaking in the catheterisation laboratory. The main limitation of intravascular imaging is that, despite the extreme miniaturisation of IVUS catheters, these probes may occlude vessels with severe stenoses, which may disturb image acquisition and interpretation. The additional information provided by IVUS on lesion composition, eccentricity and length may change treatment strategies in up to 20% of cases.

#### **Non-Stent Based PCI**

Contemporary PCI techniques are essentially based on stents, but balloon angioplasty remains an integral step in the procedure. In addition, atherectomy and plaque modification strategies remain necessary in some procedures. Thus, understanding of the mechanisms and proper utilisation of these techniques remain important in the modern era. The importance of intravascular imaging is likely amplified in non stent-based interventions with the goal of maximal luminal gain and minimal risk of dissection and vessel perforation. Selection of the device size can be based on measurements of the total vessel (i.e. EEM) diameter, although a more conservative approach matching balloon size to that of lumen diameter of the distal reference segments is most routinely performed in practice.

#### **Stent-Based PCI**

Stents have become standard in virtually every percutaneous coronary intervention. IVUS has played a critical role in the establishment of modern stent deployment technique. IVUS provides cross-sectional views of the stent and its interaction with the vessel wall, enabling unique assessment of expansion, apposition, vessel dissection and residual untreated disease that cannot be properly defined by angiography. The pioneer report of Colombo and co-workers revealed a mean residual stenosis of 51 percent following angiography-guided stent deployment and a high prevalence of incomplete stent apposition. This significantly altered the understanding of optimal stent deployment and prevention of subacute thrombosis.

After balloon inflations at higher pressures (typically 18 – 20 atm), use of a larger balloon or both, the operators were able to reduce the residual stenosis to 34 percent, which likely led to a 0.3% rate of subacute thrombosis without the need for systemic post-procedure anticoagulation. However, restenosis remained an important limitation of bare metal stents, affecting approximately 20 to 40 percent of patients.

“The bigger the better” adage has dominated the interventional cardiology approach for decades derived from angiographic assessment of lumen gain and late loss, but also suggests the importance of IVUS to optimise stent expansion and maximise lumen gain without the risk of vascular complication. The landmark MUSIC registry helped defined IVUS criteria for optimal stenting and was based on three variable factors:

1. Complete apposition of the stent over its entire length;
2. Symmetric stent expansion defined by the ratio of minimal/maximal lumen diameter  $\geq 0.7$ , and
3. In-stent minimal lumen area  $\geq 90$  percent of the average area of distal and proximal references or  $\geq 100$  percent of the lumen area of the reference segment with the smallest lumen area.

The subgroup of patients who met the criteria had a record eight percent rate of restenosis after bare metal stent implantation. However, the criteria are difficult to achieve in real practice. In the Optimal Stent Implantation Trial, stents were post-dilatated at 18 atmospheres and only 60 percent reached MUSIC criteria. In the Angiography Versus Intravascular Ultrasound Directed stent placement (AVID) trial, the more liberal goal of in-stent lumen CSA,  $\geq 90$  percent of the distal reference area, was not achieved in  $> 70$  percent of 225 patients. Other adaptations to the criteria have been suggested:

- a) 80 percent average reference area and 90 percent lumen area of the reference segment with the smallest area;
- b) Minimal in-stent lumen area is  $\geq 9\text{mm}^2$ , and
- c) Ratio of stent area to reference EEM area  $\geq 0.55$ . However, these commonly employed IVUS endpoints based on a predefined stent-to-reference ratio are also difficult to achieve.

#### **Clinical Studies Test Hypothesis**

Several prospective clinical studies were conducted to test the hypothesis that IVUS guidance of stent deployment improves outcomes, but results are conflicting. CRUISE was a large observational sub-study involving 538 patients from the Stent Anticoagulation Regimen Study (STARS) a randomised multicentre trial testing different anti-thrombotic regimens that compared angiographic versus ultrasound guidance on a centre-by-centre basis.

The study showed improvement in the rates of target vessel repeat revascularisation after nine months in patients treated at centres using the IVUS-guided approach. In the “Optimisation with ICUS” (OPTICUS) study, IVUS and angiographic-guided approaches resulted in similar rates of both angiographic restenosis and need for target vessel revascularisation. The TULIP study suggested that routine IVUS guidance for stent deployment was likely to be of benefit only in patients with a high risk for restenosis. A large retrospective study including 884 patients compared outcomes of IVUS-guided versus a propensity-score matched population undergoing DES implantation with angiographic guidance alone. The study showed that IVUS-guidance during DES implantation reduced both DES thrombosis and the need for repeat revascularisation.

#### **Safety Over Efficacy**

However, the focus of contemporary interventional cardiology has shifted towards improving the safety rather than efficacy of drug-eluting stents (DES), as these devices virtually eliminated the problem of restenosis, but have been associated with late thrombosis. IVUS studies were important to provide a morphological analysis of the local biological effects of the implantation of DES.

Initial IVUS studies were essentially to confirm suppression of neointimal hyperplasia by DES. These studies also revealed the occurrence of new late incomplete stent apposition, which has been anecdotally associated with thrombosis. While no large randomised study has been conducted to support the approach of IVUS-guided DES deployment, the use of IVUS has increased over the past year. A large single retrospective study recently demonstrated that the use of IVUS improved outcomes of patients undergoing DES implantation.

Diseased bypass grafts have been a challenge for both interventionists and cardiac surgeons. Intravascular imaging is important to guide stent size selection and define extent of disease. IVUS has also been used to monitor outcomes after treatment of vein grafts with DES. The SECURE study included 76 patients (n = 94 lesions) with graft disease treated with a sirolimus eluting stent, and 14 patients had IVUS follow-up performed

at eight months.

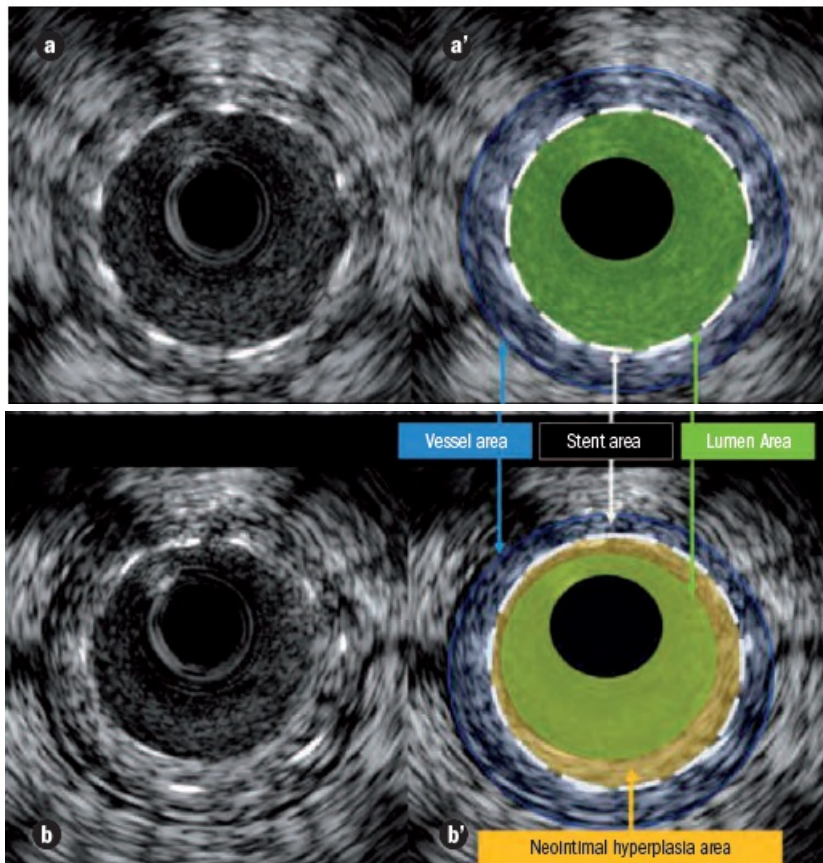
Overall, the percentage of intimal hyperplasia was  $11.8 \pm 16.5$  percent and half of the patients with graft sirolimus-eluting stent had  $< 1$  percent intimal hyperplasia. In the setting of a randomised trial, 75 patients with graft disease (96 lesions) that received either sirolimus-eluting stents or bare metal stents (RRISC study) were assessed by IVUS at six months.

Sirolimus-eluting stents showed smaller neointimal hyperplasia volume compared with BMSs ( $1.3$  vs.  $24.5$  mm<sup>3</sup>,  $p < 0.001$ ). In the sirolimus-eluting stent group, there was a greater intimal hyperplasia at overlapping sites as compared to non-overlapping segments.

### Conclusion

At present, the main purpose of IVUS is to improve our understanding of atherosclerotic disease and to define its natural history. Ultimately, the aim is to identify patients at high risk for future cardiovascular events and to evaluate the benefits from either local or systemic therapeutic interventions. To this end, a proper and careful acquisition process, analysis and reporting of the technique is recommended.

**Figure 3.** IVUS stent appearance and imaging of restenosis. Panel a shows a frame of a coronary vessel after stenting. Panel a' depicts the vessel area (blue), the stent area (dotted white line) and the lumen area (green). While panel b depicts an image of the same stent at 6 months follow-up. In panel b' the neointimal hyperplasia area is highlighted in yellow.



A full set of references for this article is available on request to the Managing Editor, at [edi.torial@cardiologymanagement.eu](mailto:edi.torial@cardiologymanagement.eu)

Published on : Sun, 31 Jan 2010