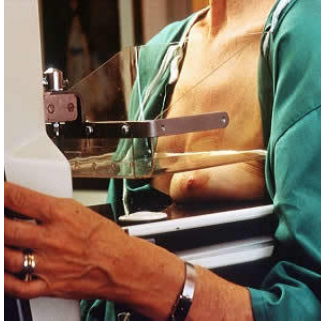

Focal Breast Pain: Does Breast Density Affect the Need for Ultrasound?



Directed ultrasound, when performed in conjunction with digital mammography for the evaluation of focal breast pain in women with nondense breasts, is of low utility and may contribute to unnecessary intervention because of incidental findings, according to a new study published in *Academic Radiology*.

See Also: [Breast Density and Choosing Optimal Breast Screening](#)

This study is the largest to evaluate the long-term outcomes and utility of both digital mammography and ultrasound in the workup of primary focal breast pain, i.e., pain within one breast quadrant that is localisable by one finger and whose presentation is not associated with other symptoms. It is also the first to stratify findings by mammographic density and assess the role of digital mammography and directed ultrasound in dense and nondense breasts.

Researchers retrospectively reviewed 3,411 consecutive cases of primary breast pain evaluated by digital mammography and directed ultrasound over a six-year period. Women with primary focal breast pain, who were initially evaluated with both mammography and ultrasound, and who underwent at least two years of breast imaging follow-up ($n = 2,415$), were included. Women who presented with diffuse, radiating, or axillary pain, associated palpable findings at the site of pain, skin changes, or nipple changes (discharge, retraction) were excluded. Women who were either pregnant or breast-feeding, reported a history of recent trauma or infection of the affected breast, or had a history of ipsilateral breast cancer were also excluded. The final study group consisted of 413 cases in 369 women.

The researchers found that inclusion of directed ultrasound as part of the diagnostic workup for primary focal breast pain did not yield any cancer diagnoses. However, breast density had a differential effect on the ability to detect benign abnormalities at the site of focal breast pain. They reported these key findings:

- Overall, 18 percent (76 of 413) of cases demonstrated imaging abnormalities. Of these, 74 percent (56 of 76) occurred in dense breasts and 26 percent (20 of 76) in nondense breasts.
- 70 percent of lesions in nondense breasts were seen with mammography and ultrasound, whereas 30 percent were detected only with ultrasound.
- Of lesions detected in dense breasts, 29 percent were seen with mammography and ultrasound, whereas 71 percent were detected only with ultrasound.

In addition, 31 percent (24 of 76) of cases were biopsied, 42 percent (10 of 24) of which were detected by ultrasound only. No cancer was detected in initial workup. At two-year followup, three women, all with dense breasts, developed cancer in the same quadrant as the initial pain.

"Limitations in our study include the absence of malignancy on initial imaging workup of focal breast pain, despite a large sample size ($n = 413$). Because of the rarity of malignancy associated with focal breast pain, it is difficult to evaluate the utility of digital mammography and ultrasound as the sensitivity cannot be calculated. This seems to be a pervasive limitation in the literature," write the authors, who are affiliated with the Department of Radiology at Duke University Medical Center.

Source: [Academic Radiology](#)
Image Credit: Wikimedia Commons

Published on : Tue, 3 Jan 2017