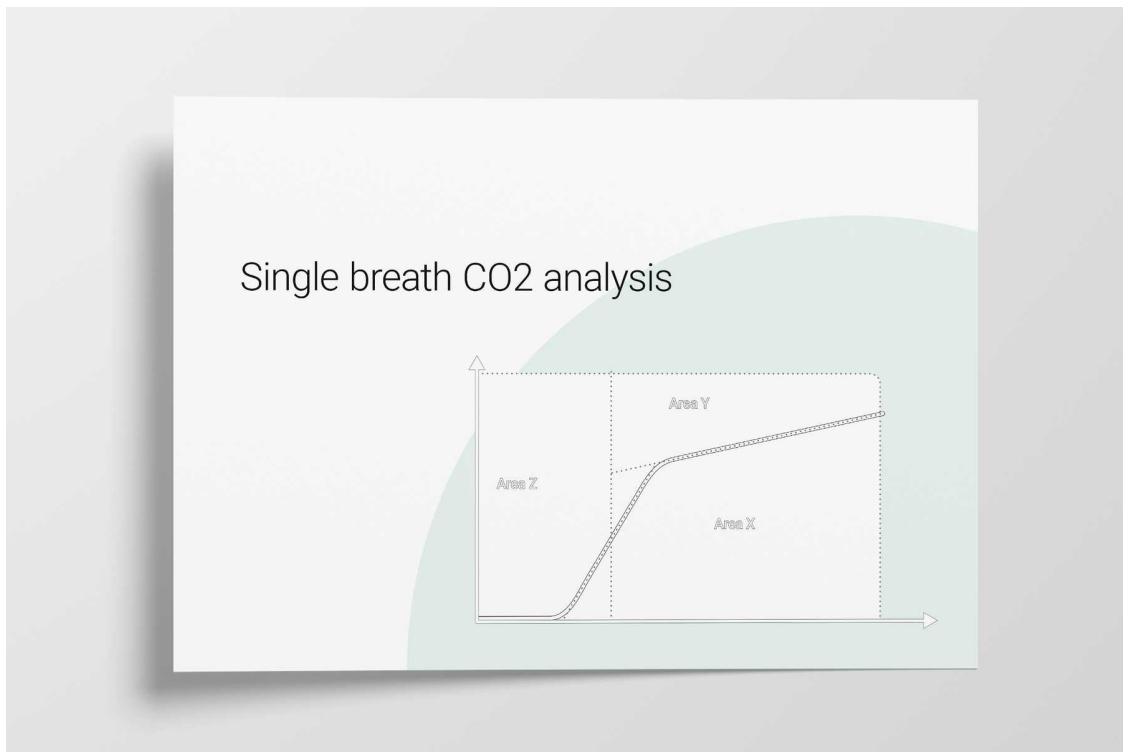


Basics of Volumetric Capnography - Part 2: Single Breath CO₂ Analysis

Anatomical dead space, alveolar dead space, and CO₂ elimination: Learn how they can give you an insight into the patient's lung condition.



Single breath CO₂ analysis: insight into the patient's lung condition

The volumetric capnogram can also be divided into three areas:

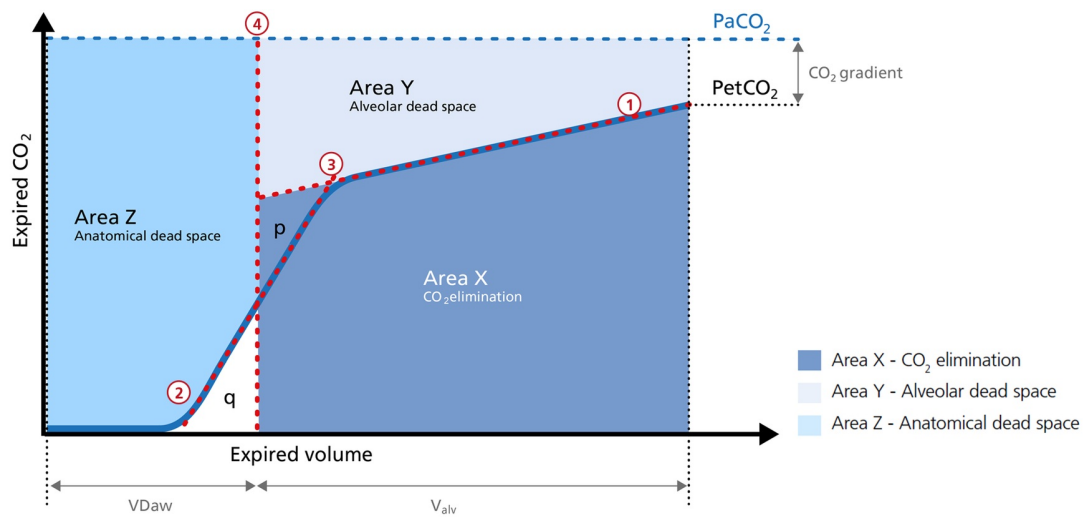
- Area X - CO₂ elimination
- Area Y - Alveolar dead space
- Area Z - Anatomical dead space

The size of the areas, as well as the form of the curve, can give you more insight into the patient's lung condition regarding:

- Dead space fraction - V_{Daw} / V_{TE}
- Alveolar minute ventilation - V'_{alv}

In the illustration (Figure 1) you can see:

1. Slope of Phase III
2. Slope of Phase II
3. The intersection of lines 1 and 2 defines the limit between Phases II and III
4. A perpendicular line is projected onto the X-axis and its position is adjusted until the areas p and q on both sides become equal



1. Slope of Phase III
2. Slope of Phase II
3. The intersection of lines 1 and 2 defines the limit between Phases II and III.
4. A perpendicular line is projected onto the x-axis and its position is adjusted until the areas p and q on both sides become equal.

Figure 1: The three areas of the volumetric capnogram

Area X - CO₂ elimination ($V'CO_2$)

Area X represents the actual volume of CO₂ exhaled in one breath ($V_{E}CO_2$). Adding up all of the single breaths in one minute gives you the total elimination of CO₂ per minute ($V'CO_2$). If cardiac output, lung perfusion, and ventilation are stable, this is an assessment of the production of CO₂ called $V'CO_2$. The $V'CO_2$ value displayed on the ventilator can be affected by any change in CO₂ production, cardiac output, lung perfusion, and ventilation. It indicates instantly how the patient's gas exchange responds to a change in ventilator settings. [Monitoring trends allows for detection of sudden and rapid changes in \$V'CO_2\$](#) (Figure 2).

Good to know:

Decreasing $V'CO_2$: Hypothermia, deep sedation, hypothyroidism, paralysis, and brain death decrease CO₂ production and induce a decrease in $V'CO_2$. Decreasing $V'CO_2$ can also be due to a decrease in cardiac output or blood loss, and may also suggest a change in blood flow to the lung areas. Pulmonary embolism, for example, exhibits $V'CO_2$ reduction and a slope reduction in Phase II.

Increase in $V'CO_2$: An increase in $V'CO_2$ is usually due to bicarbonate infusion or an increase in CO₂ production that can be caused by:

- Fever
- Sepsis
- Seizures
- Hyperthyroidism
- Insulin therapy

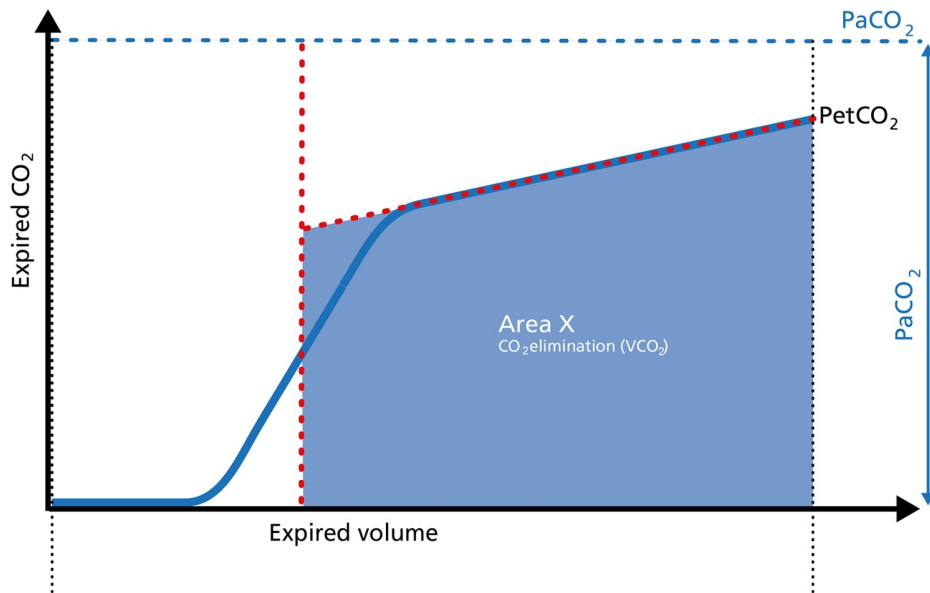


Figure 2: Area X of the volumetric capnogram

Area Y - Alveolar dead space

Area Y represents the amount of CO₂ that is not eliminated due to alveolar dead space (Figure 3).

Good to know:

Increase: Alveolar dead space is increased in cases of lung emphysema, lung overdistension, pulmonary embolism, pulmonary hypertension, and cardiac output compromise.

Decrease: If the above mentioned conditions improve due to successful therapy, the alveolar dead space decreases.

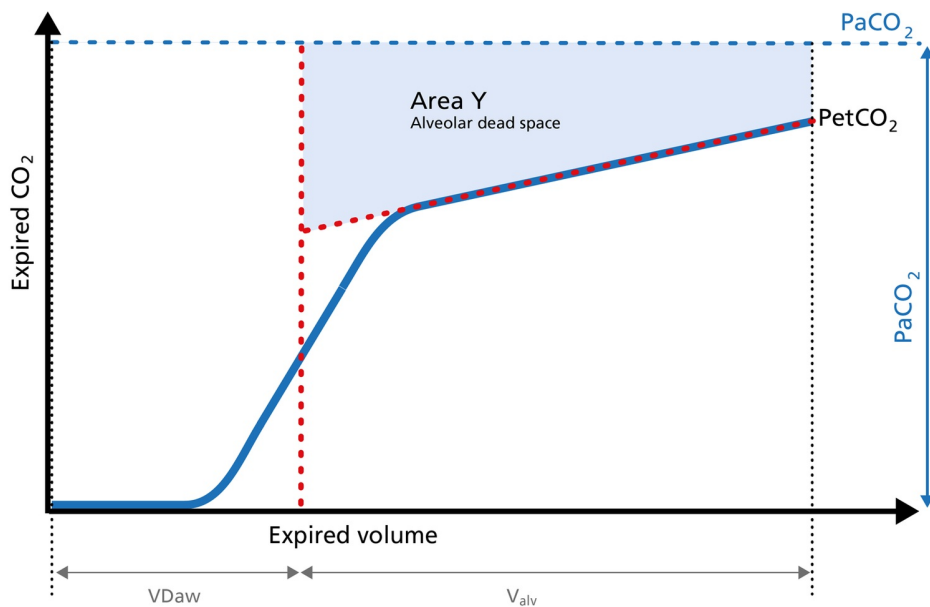


Figure 3: Area Y of the volumetric capnogram

Area Z - Anatomical dead space

Anatomical dead space measurement using a volumetric capnogram gives an effective, in-vivo measure of volume lost in the conducting airway. This area represents a volume without CO₂. It does not take part in the gas exchange and consists of the airway, endotracheal tube, and artificial accessories, such as a flextube positioned between the CO₂ sensor and the patient (Figure 4).

Good to know:

Expansion of Area Z: An expansion of Area Z can indicate an increase in anatomical dead space ventilation (VDaw). Consider a reduction in your artificial dead space volume.

Diminution of Area Z: A diminution of Area Z is seen when the artificial dead space volume is decreased and when excessive PEEP is decreased.

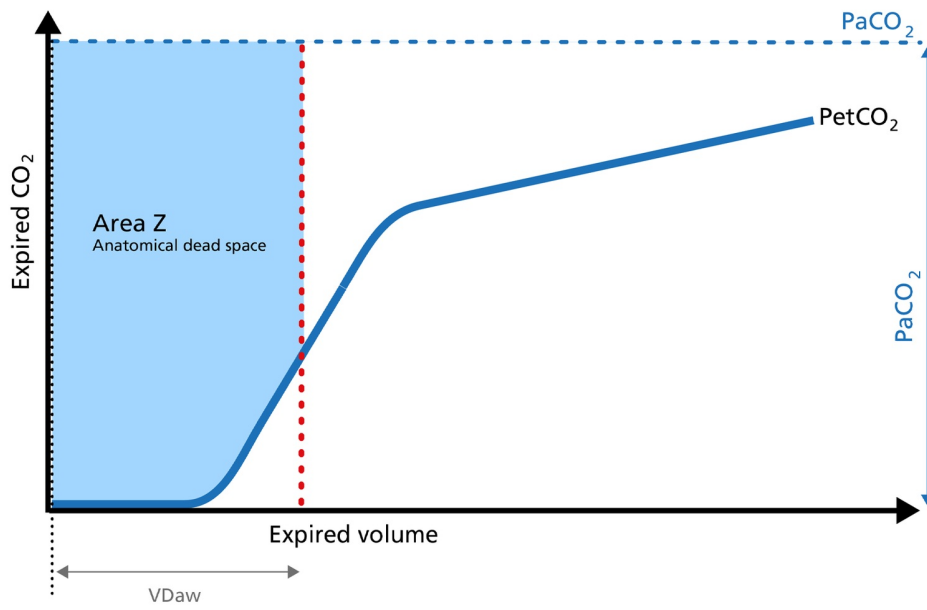


Figure 4: Area Z of the volumetric capnogram

Alveolar minute ventilation - V'alv

Phase III of the waveform represents the quantity of gas that comes from the alveoli and actively participates in gas exchange. [V'alv is calculated](#) by subtracting the anatomical dead space (VDaw) from the tidal volume (VTE) multiplied by the respiratory rate from the minute volume (MinVol): $V'alv = RR * Vtalv = RR * (VTE - VDaw)$ (Figure 5).

Good to know:

Increase: An increase in V'alv is seen after an efficient recruitment maneuver and induces a transient increase in V'CO₂.

Decrease: A decrease in V'alv can indicate that fewer alveoli are participating in the gas exchange, for example, due to pulmonary edema.

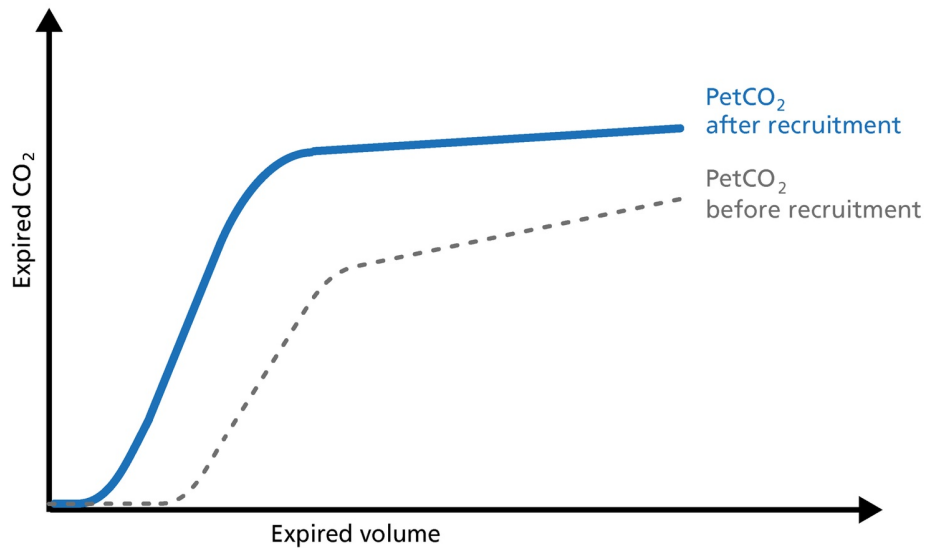


Figure 5: PetCO₂ before and after recruitment

Dead space ventilation - V_{Daw}/V_T ratio

The ratio of airway dead space (V_{Daw}) to tidal volume (V_T) - the V_{Daw}/V_T ratio - gives you an [insight into the effectiveness of ventilation](#) (Figure 6).

Good to know: A rising V_{Daw}/V_T ratio can be a sign of ARDS.

- In a normal lung, the V_{Daw}/V_T ratio is between 25% and 30%.
- In early ARDS, it is between 58% and up to 83%.

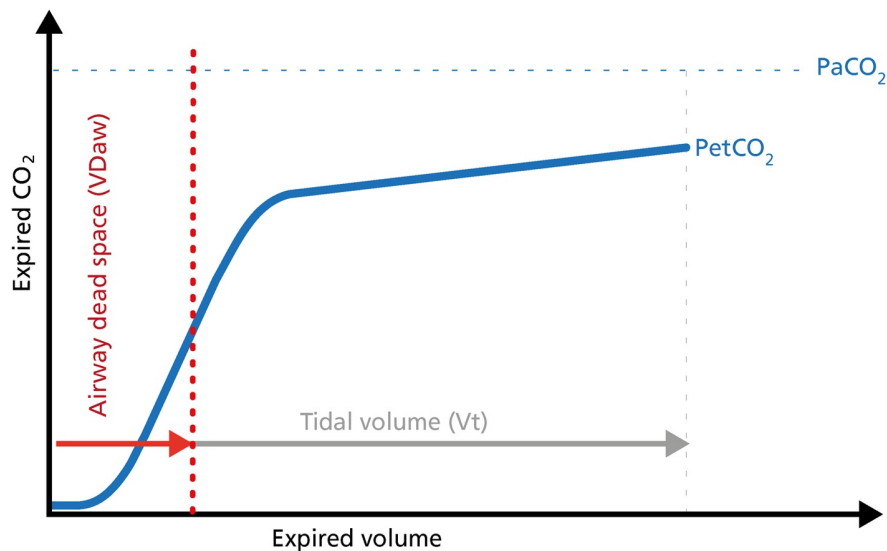


Figure 6: Dead space ventilation

Volumetric capnography on Hamilton Medical ventilators

All [Hamilton Medical ventilators offer volumetric capnography](#) (All models except HAMILTON-MR1A). It is available as an option on the HAMILTON-C6, the HAMILTON-G5, the HAMILTON-C3, and the HAMILTON-C1/T1, and as a standard feature on the HAMILTON-S1.

Author: Karjaghli Munir, Respiratory Therapist, Hamilton Medical Clinical Application Specialist; Matthias Himmelstoss, ICU Nurse, MSc Physics, Product Manager

Date of first publication: 16.11.2023

Source: [Hamilton Medical](#)

References:

1. Anderson JT, Owings JT, Goodnight JE. Bedside noninvasive detection of acute pulmonary embolism in critically ill surgical patients. *Arch Surg.* 1999;134(8):869-875. doi:10.1001/archsurg.134.8.869
2. Aström E, Niklason L, Drefeldt B, Bajc M, Jonson B. Partitioning of dead space—a method and reference values in the awake human. *Eur Respir J.* 2000;16(4):659-664. doi:10.1034/j.1399-3003.2000.16d16.x
3. Blanch L, Romero PV, Lucangelo U. Volumetric capnography in the mechanically ventilated patient. *Minerva Anestesiol.* 2006;72(6):577-585.
4. Eriksson L, Wollmer P, Olsson CG, et al. Diagnosis of pulmonary embolism based upon alveolar dead space analysis. *Chest.* 1989;96(2):357-362. doi:10.1378/chest.96.2.357
5. Fletcher R, Jonson B, Cumming G, Brew J. The concept of deadspace with special reference to the single breath test for carbon dioxide. *Br J Anaesth.* 1981;53(1):77-88. doi:10.1093/bja/53.1.77
6. Kallet RH, Daniel BM, Garcia O, Matthay MA. Accuracy of physiologic dead space measurements in patients with acute respiratory distress syndrome using volumetric capnography: comparison with the metabolic monitor method. *Respir Care.* 2005;50(4):462-467.
7. Kiiski R, Takala J. Hypermetabolism and efficiency of CO₂ removal in acute respiratory failure. *Chest.* 1994;105(4):1198-1203. doi:10.1378/chest.105.4.1198
8. Kumar AY, Bhavani-Shankar K, Moseley HS, Delph Y. Inspiratory valve malfunction in a circle system: pitfalls in capnography. *Can J Anaesth.* 1992;39(9):997-999. doi:10.1007/BF03008353
9. Nuckton TJ, Alonso JA, Kallet RH, et al. Pulmonary dead-space fraction as a risk factor for death in the acute respiratory distress syndrome. *N Engl J Med.* 2002;346(17):1281-1286. doi:10.1056/NEJMoa012835
10. Eriksson L, Wollmer P, Olsson CG, et al. Diagnosis of pulmonary embolism based upon alveolar dead space analysis. *Chest.* 1989;96(2):357-362. doi:10.1378/chest.96.2.357
11. Pyles ST, Berman LS, Modell JH. Expiratory valve dysfunction in a semiclosed circle anesthesia circuit—verification by analysis of carbon dioxide waveform. *Anesth Analg.* 1984;63(5):536-537.
12. RADFORD EP Jr. Ventilation standards for use in artificial respiration. *J Appl Physiol.* 1955;7(4):451-460. doi:10.1152/jappl.1955.7.4.451
13. Rodger MA, Jones G, Rasuli P, et al. Steady-state end-tidal alveolar dead space fraction and D-dimer: bedside tests to exclude pulmonary embolism. *Chest.* 2001;120(1):115-119. doi:10.1378/chest.120.1.115
14. Yaron M, Padyk P, Hutsiniller M, Cairns CB. Utility of the expiratory capnogram in the assessment of bronchospasm. *Ann Emerg Med.* 1996;28(4):403-407. doi:10.1016/s0196-0644(96)70005-7
15. Wolff G, Brunner JX, Grädel E. Gas exchange during mechanical ventilation and spontaneous breathing. Intermittent mandatory ventilation after open heart surgery. *Chest.* 1986;90(1):11-17. doi:10.1378/chest.90.1.11
16. Wolff G, X. B. J. , Weibel W., Bowes C.L. , Muchenberger R., Bertschmann W. (1989). Anatomical and series dead space volume: concept and measurement in clinical practice. *Applied cardiopulmonary pathophysiology*, 2, 299-307.

Published on : Fri, 9 Feb 2024