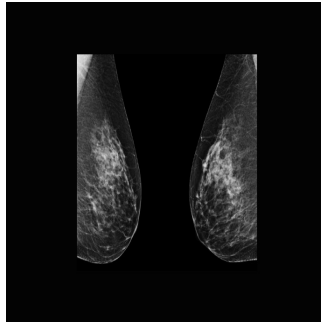


---

## Abbreviated MRI as a Supplemental Cancer Screening Tool for Dense Breasts



---

Mammography is the main method for breast cancer screening but is less effective for individuals with dense breast tissue, who have a higher risk of cancer. Contrast-enhanced MRI is more sensitive but expensive and time-consuming. An abbreviated MRI (AB-MR) protocol shows promise in maintaining sensitivity while reducing time and cost. Studies comparing AB-MR to other methods show higher cancer detection rates. However, there's limited data on AB-MR's effectiveness beyond the initial screening round. This study aims to compare the outcomes of baseline and subsequent rounds of AB-MR screening in individuals with dense breasts at average risk of breast cancer.

### **Penn Medicine Retrospective Study on Abbreviated MRI Screening Efficacy**

In this retrospective study conducted at Penn Medicine, data from 2585 abbreviated MRI (AB-MR) examinations were analysed. These examinations were performed between December 20, 2016, and May 10, 2023, on patients with dense breasts who met specific criteria for AB-MR screening. The study was exempted by the institutional review board and was HIPAA compliant, with the requirement for written informed consent waived.

The AB-MR screenings were conducted at a single academic health system comprising five regional medical centres, including urban academic and community practices. Patients eligible for AB-MR screening had mammographically heterogeneously or extremely dense breasts and had undergone a screening mammogram within the prior 11 months, assessed as BI-RADS category 1 or 2.

Data collection was performed using the electronic medical record (EMR). The final study sample included 2585 AB-MR examinations in 2007 patients. Each examination was classified as either a baseline examination (the patient's first AB-MR examination) or a subsequent-round examination.

The AB-MR examinations were performed using various MRI systems and bilateral breast coils, following a specific imaging protocol consisting of axial sequences including STIR, pre-contrast fat-suppressed T1-weighted sequence, and single-timepoint post-contrast T1-weighted sequence. An axial DWI sequence was added to the protocol in a subset of examinations.

The AB-MR studies were interpreted by subspecialty-trained breast radiologists using the ACR BI-RADS MRI lexicon. Biopsy outcomes were assessed for patients with BI-RADS categories 4 or 5, and cancer characteristics were recorded, including cancer stage at diagnosis, histology, receptor status, tumour size, and nodal status.

A reference standard for cancer detection by AB-MR was established through EMR review, identifying any histologic diagnosis of breast cancer within a 1-year follow-up period after AB-MR examination.

Overall, the study aimed to evaluate the performance and effectiveness of AB-MR screening in detecting breast cancer in individuals with dense breasts, both in baseline and subsequent-round screenings, within the context of an academic health system.

### **Characterising Patients and Screening Patterns**

The final study sample comprised 2585 AB-MR examinations, consisting of 2007 baseline examinations and 578 subsequent-round examinations. Among the 2007 patients, 78.8% underwent only a baseline examination, while 22.2% underwent multiple examinations, ranging

from 2 to 5. Patient demographics showed a mean age of 57.1 years for all examinations, with variations in age distribution between baseline and subsequent-round examinations. The majority of patients were White, followed by Black, Asian, and other race categories. Most examinations showed heterogeneously or extremely dense breast tissue. Background parenchymal enhancement (BPE) was moderate or marked in about a fifth of examinations. The mean interval between subsequent-round examinations was 761 days, with a median of 745 days. These findings provide insight into the demographics and characteristics of patients undergoing AB-MR screening for breast cancer detection.

### **Screening interval for AB-MR for cost-effectiveness and accessibility**

In this large-scale retrospective study, the effectiveness of abbreviated MRI (AB-MR) as a supplemental screening tool for individuals with dense breasts and average breast cancer risk was thoroughly evaluated. The focus was on comparing the performance metrics between baseline and subsequent-round AB-MR examinations.

The study encompassed a comprehensive analysis of real-world data, providing valuable insights into the utility of AB-MR in clinical practice. Notably, the abnormal interpretation rate (AIR) was found to be significantly lower for subsequent-round AB-MR examinations compared to baseline rounds. However, despite this reduction in AIR, subsequent-round AB-MR examinations exhibited a notably high cancer detection rate (CDR) of 12.1 per 1000, which was comparable to the CDR for baseline examinations (18.9 per 1000). Moreover, the positive predictive values (PPV2 and PPV3) did not show statistically significant differences between baseline and subsequent-round AB-MR examinations.

An essential aspect of the study was the characterisation of the cancers detected by subsequent-round AB-MR examinations, all of which were early-stage malignancies. These findings underscored the efficacy of AB-MR in identifying breast cancers at an early phase, facilitating timely intervention and potentially improving patient outcomes.

Comparisons with prior investigations highlighted variations in CDRs, reflecting differences in patient populations, reader expertise, and screening intervals. The study's findings suggested that the screening interval for AB-MR could be optimised to balance early cancer detection with practical considerations such as cost-effectiveness and accessibility.

However, the study also acknowledged several limitations, including the absence of long-term outcome data on breast cancer mortality, potential variability in patient selection criteria, and limited racial diversity in the study sample. These factors underscored the need for further research to refine screening protocols and assess the impact of AB-MR on patient outcomes comprehensively.

Overall, the study provided robust evidence supporting the use of sequential AB-MR examinations for supplemental breast cancer screening in individuals with dense breasts and average breast cancer risk. Nevertheless, ongoing investigations are warranted to optimise screening intervals and evaluate the long-term benefits of AB-MR in clinical practice.

**Source:** [American Journal of Roentgenology](#)

**Image Credit:** [iStock](#)

Published on : Tue, 28 May 2024