

SPECIAL SUPPLEMENT
Aspen Symposium
during ESICM 2018

Imaging

Imaging and intensive care medicine: an evolving partnership, *A. McLean*

Whole-body ultrasound in the intensive care unit: bedside ultrasound of the whole body, *A. Denault et al.*

Clinical assessment of critically ill patients by whole-body ultrasonography, *R. Wiersema et al.*

Using ultrasound to prevent diaphragm dysfunction, *T. Schepens & E.C. Goligher*

Imaging and ICU: advice from a radiologist, *M. Sánchez*

Abdominal point-of-care ultrasound in critical care: the secrets of the abdomen, *J. Wilkinson et al.*

Multimodal neuromonitoring catheter insertion: secondary complications, *I. González & D. Santamarta*

Required and preferred scanner features for different ultrasound applications: executive summary, *ECRI Institute*

PLUS

Advances in monitoring expired CO₂ in critically ill patients, *M. Mezyd & JC Richard*

How to manage severe dengue infection, *S. Jog et al.*

Antifungal treatment in the ICU: best practice in managing fungal infections, *A. Cortegiani & M. Bassetti*

Interprofessional teamwork in the ICU: panacea or illusion? *A. Xyrichis*

Dr. Theodoros Kyprianou joins Editorial Board, *K. Theodoros*





Tom Schepens

Staff Physician
Paediatric Intensive Care Unit
Department of Critical Care
Medicine
Antwerp University Hospital
University of Antwerp
Edegem, Belgium

tomschepens@gmail.com



Ewan C. Goligher*

Assistant Professor of Medicine
Interdepartmental Division of
Critical Care Medicine
University of Toronto

Department of Medicine
Division of Respiratory
University Health Network
Toronto, Canada

Physician-scientist
Toronto General Hospital Re-
search Institute
Toronto, Canada

ewan.goligher@mail.utoronto.ca

* corresponding author

Using ultrasound to prevent diaphragm dysfunction

Diaphragm ultrasound is a valuable tool to diagnose and prevent ventilator-induced diaphragm dysfunction. This review focuses on the use of ultrasound to assess diaphragm structure and function in ventilated patients.

a low-frequency phased array transducer can be used to quantify downward excursion of the diaphragm in M-mode. The probe is positioned subcostally at the mid-clavicular line and angled upward, so that the ultrasound beam projects perpendicular to the dome of the diaphragm—the probe may be angled slightly medially if needed. **Figure 1** shows an example of the images obtained with this approach. Normal values of diaphragm excursion during various inspiratory manoeuvres have been reported and the technique has excellent reproducibility (Boussuges et al. 2009). This evaluation is only valid in the absence of ventilatory support, as thoracic insufflation by applied positive pressure will also lead to downward diaphragm excursion.

Widespread implementation of diaphragm ultrasound in clinical practice has the potential to improve outcome

The second approach measures diaphragm cross-sectional thickness in the zone of apposition. A high-frequency linear array transducer can be employed to measure the cross-sectional thickness of the diaphragm (B-mode) and the percentage change in thickness from expiration to inspiration, referred to as the thickening fraction (TF) (M-mode) (**Figure 2**) (Sarwal et al. 2013; Matamis et al. 2013). This technique has been described extensively and is well validated (Cohn et al. 1997). The probe is positioned in the 8th or 9th intercostal space between the mid- and anterior axillary lines

in the zone of apposition. The diaphragm is visualised as the space intervening between the pleural and peritoneal lines. Both thickness and thickening fraction measurements show excellent reproducibility in ventilated patients (Goligher, Laghi et al. 2015).

Application: monitoring diaphragm function

Both measurements can help to diagnose diaphragm dysfunction. Reduced excursion during various inspiratory manoeuvres is an established diagnostic criterion for dysfunction (Lerolle et al. 2009). Serial measurements of diaphragm thickness can reveal acute decreases in diaphragm thickness, indicative of rapid muscle atrophy. As the thickening fraction is related to the degree of diaphragmatic shortening during inspiration, it correlates with the changes in lung volume (Wait and Johnson 1997; Wait et al. 1989), inspiratory pressure development (Ueki et al. 1995; Dubé et al. 2017) and work of breathing (Vivier et al. 2012; Umbrello et al. 2015). As a result, a reduced maximal thickening fraction is a marker for diaphragm weakness. The validity of this technique to diagnose diaphragm weakness is crucially dependent on obtaining maximal volitional inspiratory effort. Using ultrasound to diagnose diaphragm weakness may help to guide the management of patients with difficult weaning from mechanical ventilation (Vorona et al. 2018; Heunks et al. 2015).

The thickening fraction measured during a spontaneous breathing trial (SBT) predicts the weaning outcome (DiNino et al. 2014; Zambon et al. 2016). In contrast to commonly used parameters like the rapid shallow breathing index (RSBI), the thickening fraction specifically reflects diaphragmatic action. This

The diaphragm is the primary muscle of inspiration. It is a thin dome-shaped muscle that inserts into the lower ribs, xiphoid process, and lumbar vertebrae. It runs parallel to the rib cage in the zone of apposition before curving along the inferior pleural surface (Mead 1979). Shortening of the diaphragm muscle fibres during inspiration results in a piston-like action, drawing the lungs downward and forcing the lower chest wall outward (de Troyer and Loring 2011; Gauthier et al. 1994). Downward excursion of the diaphragm varies from about 1 cm during normal tidal breathing to over 1–2 cm during deep inspiration. Diaphragm function is a crucial determinant of respiratory capacity in respiratory failure; injury to the diaphragm in the intensive care unit (ICU) has a substantial impact on patient outcome (Dres et al. 2017; Goligher et al. 2018). Recent advances in ultrasound imaging enable clinicians to more feasibly assess diaphragm function and potentially protect the diaphragm during mechanical ventilation.

Diaphragm ultrasound techniques

Two techniques to image the diaphragm using ultrasound have been described. First,

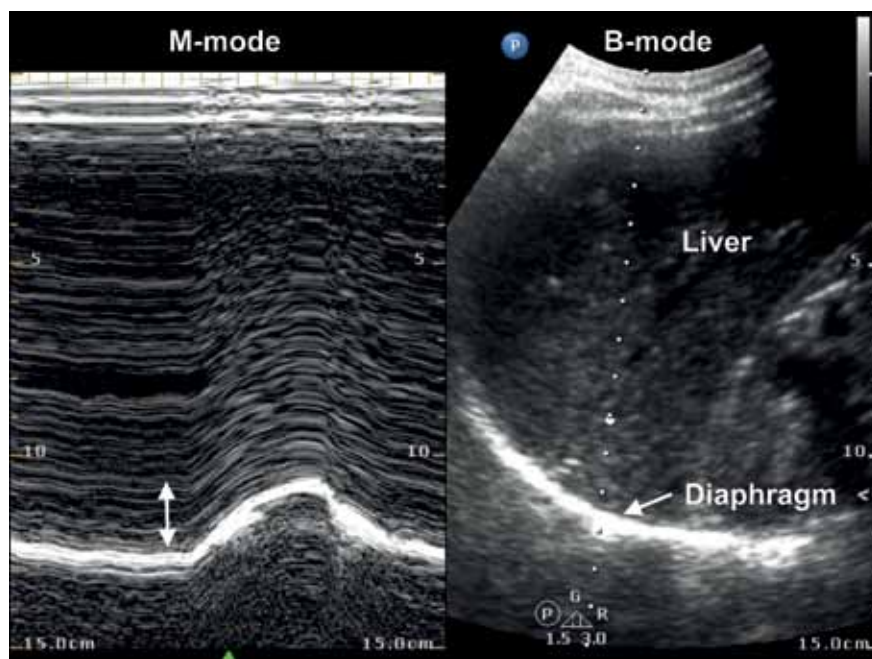


Figure 1. B-mode (right) and M-mode (left) ultrasound images of the diaphragm. The M-mode image shows downward diaphragm excursion during inspiration, i.e. towards the ultrasound probe positioned subcostally.

deleterious changes in diaphragm thickness and poor clinical outcomes (Goligher et al. 2018). Insufficient activity leads to rapid disuse atrophy (Levine et al. 2008; Goligher, Fan et al. 2015; Goligher et al. 2018); some evidence suggests that excessive respiratory muscle loading may result in inflammation, injury and dysfunction (Reid et al. 1994; Jiang et al. 2012), although it is unclear whether this happens frequently in the clinical setting.

Monitoring diaphragm activity by ultrasound might be used to guide the titration of ventilatory support. By targeting support levels producing relatively normal levels of respiratory effort (thickening fraction in the range of 15-30%), diaphragm atrophy and injury might be prevented. This concept is referred to as diaphragm-protective ventilation (Heunks and Ottenheim 2018). A recent study found that the length of ICU stay, the duration of ventilation, and the risk of complications of respiratory failure (prolonged ventilation, reintubation, tracheostomy or death) were minimised when patients' thickening fraction averaged 15-30%—similar to that of healthy subjects breathing at rest—during the first 3 days of ventilation (Goligher et al. 2018). This may represent the optimal level of spontaneous breathing during mechanical ventilation to protect the diaphragm from injury (Tobin et al. 2010). Ultrasound measurements can detect adequate, insufficient or excessive inspiratory effort (see **Figure 2**) (Umbrello et al. 2015).

way, diaphragm weakness is not masked by increased accessory muscle activity during the SBT, which may explain the excellent predictive results of this parameter (DiNino et al. 2014).

Application: monitoring diaphragm activity

When the diaphragm is activated during tidal breathing, it shortens and hence thickens. This

tidal thickening is visualised on ultrasound as diaphragm thickening. Hence, diaphragm thickening fraction measurements can be used as a marker of inspiratory effort and diaphragm contractile activity, even under mechanical ventilation. Diaphragm activity during mechanical ventilation is a key determinant of the risk of diaphragm injury. Both inappropriately low or excessive levels of diaphragm activity predict the risk of

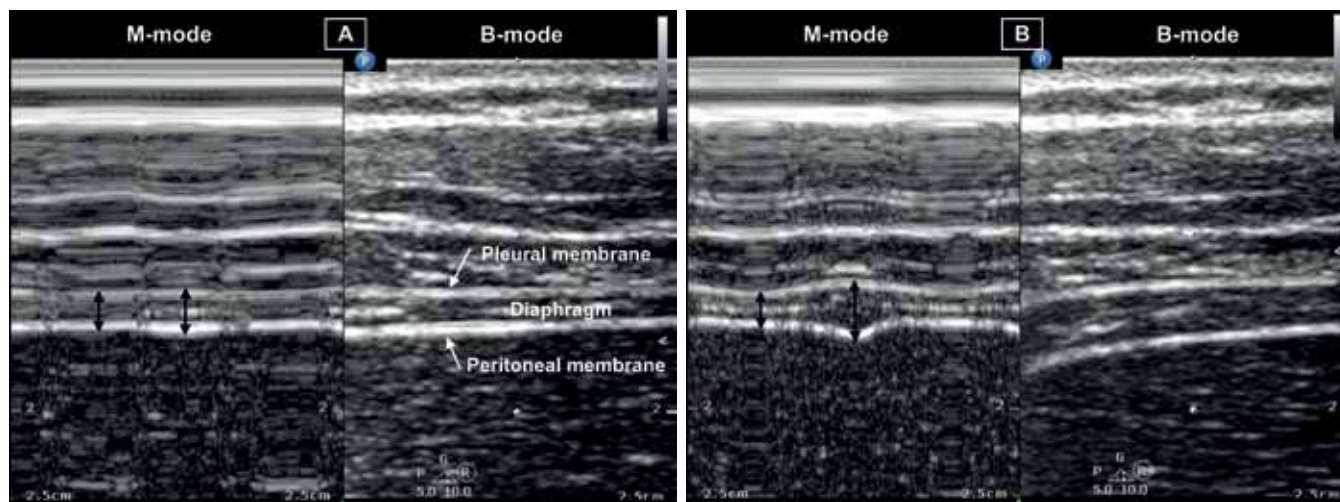


Figure 2. B-mode (right) and M-mode (left) ultrasound images of the diaphragm, measured at the zone of apposition. Measurements of the thickness (black vertical lines) during expiration (left) and inspiration (right). Figure A shows reduced diaphragm contractile activity with a small change in thickness during inspiration (thickening fraction = 13%), Figure B shows adequate diaphragm contractile activity with a larger change in thickness during inspiration (thickening fraction = 70%).

Ultrasound can also be used to diagnose patient-ventilator dyssynchrony (Thille et al. 2006; Matamis et al. 2013), as it provides real-time information of contractile activity. Recognising and treating dyssynchrony may help to improve outcomes, as frequent dyssynchrony strongly predicts poor clinical outcomes (Vaporidi et al. 2016; Blanch et al. 2015).

Future of diaphragm ultrasound

Several emerging ultrasound techniques have been evaluated for their potential to further evaluate the diaphragm. These include speckle tracking, which uses naturally occurring speckle patterns to assess tissue deformation and motion. Originating from cardiac imaging, it has been used to measure diaphragm muscle strain (Ye et al. 2013; Hatam et al. 2014). It may provide a novel noninvasive technique for bedside evaluation of respiratory workload, but further research is required to validate this technique.

Changes in diaphragm tissue structure apart from atrophy might be detected by assessing changes in diaphragm echodensity, which reflects the development of muscle oedema, inflammation and necrosis (Puthuchery et al. 2015). These provide insights on muscle quality apart from muscle bulk. This technique has been described for imaging quadriceps muscle; it has not yet been described for diaphragm ultrasound. Other ultrasound techniques including 3D imaging and elastography have yet to find their way into the ICU and clinical practice.

Conclusion

Mechanical ventilation can injure the diaphragm, resulting in significant morbidity and mortality in critically ill patients. Optimising diaphragm activity during mechanical ventilation is important to mitigate diaphragm dysfunction. Ultrasound has the capability to detect structural changes in the diaphragm (thickness and quality), assess inspiratory

effort, diagnose diaphragm weakness, predict liberation from ventilation, and possibly detect patient-ventilator dyssynchrony. Widespread implementation of diaphragm ultrasound in clinical practice has the potential to improve outcome by optimising ventilator management based on patient effort and synchrony, guiding assessment of the difficult-to-wean patient, and informing decisions about liberation from mechanical ventilation. Diaphragm ultrasound can also provide crucially important mechanistic insights for research studies: measurements of thickness, echodensity, thickening fraction, and maximal thickening may provide clinically relevant physiological biomarkers of disease and treatment effects. Future trials are required to explore how to facilitate diaphragm-protective ventilation and whether this new paradigm for ventilation improves the outcome for ventilated patients. ■

References

For full references, please email editorial@icu-management.org or visit <https://iii.hm/qp4>



Marcelo Sánchez

CDIC Teaching Coordinator
Head of Section Thoracic
Radiology
Hospital Clínic
Barcelona, Spain

MSANCHE@clinic.cat

Imaging and ICU

Advice from a radiologist

For the Imaging issue, *ICU Management & Practice* spoke to radiologist Dr. Marcelo Sanchez about radiology-ICU collaboration.

How can communication between radiology and ICU be optimised as both specialities become ever more complex?

The collaboration must be maintained by establishing protocols and consensus on image indications for the clinical processes analysed in the ICU. The best communication system is to organise multidisciplinary clinical board sessions to evaluate the cases and to create guidelines for each clinical situation. This communication is also important because clinicians consider all the ICU exams as urgent, even follow-up exams. It is important to talk not only about

the indications but also about when the exam could be done. It is important not to overload the on-call staff with urgent exams that are not really urgent.

What are the financial considerations?

The imaging budget must be adjusted to the indications established in the clinical guidelines by consensus and exceptions must be analysed to try to correct them by following up and avoiding rejecting imaging requests. We do not refuse imaging due to financial considerations; we can only discuss the medical indication.

What imaging should be done at the bedside, and what should be done in the radiology department?

The ICU doctors don't like to move their patients, but currently, only x-rays and ultrasound studies should be performed at the patient's bedside and CT or MRI studies in the radiology department. However, with new technological advances and the possibility of performing portable CT studies it will be possible to bring the radiology service closer to the ICU. ■