



Imaging the Critically Ill

The Use of Critical Care Ultrasound, E. Brogi, G. Bozzetti, M. Romani et al.

The Role of Lung Imaging to Personalise Lung Ventilation in ARDS Patients, D. Chiumello, E. Tomarchio, S. Coppola

Imaging the Critically Ill Patient: Echocardiography, L. Dragoi, G. Douflé

Point of Care Ultrasound: The Critical Imaging Tool for the Critically Unwell, C. King, J. Wilkinson, A. Miller, M. Peck

Rapid Assessment of Fluid Responsiveness and Tolerance With Ultrasound of the Neck Vessels in Critically Ill Patients, R. Flores-Ramírez, C. Mendiola-Villalobos, O. Pérez-Nieto et al.

POCUS in Critical Care Physiotherapy: Give Me Sight Beyond Sight, A. Gómez-González, M. Martínez-Camacho, R. Jones-Baro et al.

Bedside Point-of-Care Ultrasound Use in the Critically Ill: Historical Perspectives and a Path Forward, C. Bryant



Christopher King

Clinical Fellow Intensive Care
Medicine
Northampton General Hospital
Northampton, UK

chrisking01@doctors.org.uk
@chrisking01



Jonathan Wilkinson

Consultant Intensive Care
Medicine and Anaesthesia
Northampton General
Hospital
Northampton, UK

wilkinsonjonny@me.com
@wilkinsonjonny



Ashley Miller

Consultant Intensive Care
Medicine and Anaesthesia
Royal Shrewsbury Hospital
Shrewsbury, UK

ashleymiller@nhs.net
@ICMteaching



Marcus Peck

Consultant Intensive Care
Medicine and Anaesthesia
Frimley Park Hospital
Frimley, UK

drmarcuspeck@gmail.com
@ICUltrasonica

Point of Care Ultrasound: The Critical Imaging Tool for the Critically Unwell

This article aims to discuss the specific role of point of care ultrasound (POCUS) in the diagnosis and management of pathology in the critical care setting, as well as a specific tool to aid in invasive procedures. We discuss the ABCDE assessment of patients within critical care using POCUS.

requires a focused consideration of the sensitivity and specificity profile of any imaging modality selected. This provides the practitioner with a 'rule in' or 'rule out' approach, ensuring the path of least harm when basing critical treatment decisions on sonographic findings. POCUS, as the fifth pillar of clinical examination, augments the time sensitive decisions often required to reverse many life-threatening conditions, removing potential guesswork or uncertainty in their execution.

Diagnostic errors can be made when solely utilising clinical skills within such high-pressure settings. Indeed, there may be no time to wait for further diagnostic portable imaging (e.g., portable x-ray). A skilled POCUS operator can rapidly obtain answers to questions at the bedside, providing real-time information on aetiologies. Similarly, dynamic management can be instigated there and then, negating the need for further imaging, tests or transportation to distant places with its associated risks.

We live in an era of rapid technological advancement and with this, ultrasound devices have become miniaturised. Practitioners can pull these devices from their pockets as easily as a stethoscope from around the neck. Where one listened, one can see and where one imagined, one can image. It is purported that POCUS has improved diagnostic accuracy, reduced time to treatment, and potentially increased the survival of ward patients in acute respiratory or circulatory emergencies (Zieleskiewicz et al. 2021).

Specific training programmes are numerous within the United Kingdom and Europe. For example, the UK Intensive Care Society offers a structured and comprehensive accreditation programme known as FUSIC (Focused Ultrasound in Intensive Care). This modularised scheme offers accreditation in whole body ultrasound, including advanced vascular access and haemodynamic assessment. This system will be further discussed throughout this article (Intensive Care Society 2021).

This article aims to summarise and support a protocol-based approach with POCUS as a key imaging tool in the critically unwell patient, both from the initials 'A to E' and point of care assessment and for the ongoing management during an intensive care episode. It will also highlight the role of POCUS within clinical examination and its essential utilisation in procedure guidance on critical care (Figure 1).

A - AIRWAY

FUSIC airway, forthcoming

Airway ultrasound can be utilised for various purposes:

- Identification of anatomy - delineation of the relevant anatomy pertinent prior to performing a percutaneous tracheostomy, as well as real-time needle guidance. This includes identification of vascular anomalies which may either facilitate or preclude the placement of percutaneous tracheostomy on intensive care (Tremblay and Sales 2011).

Introduction

Since its introduction, the use of bedside ultrasound has become a ubiquitous examination tool in modern intensive care medicine. It has seen exponential growth, often being the go-to diagnostic and therapeutic imaging modality for specific system-based pathologies. Moreover, it has been utilised in the monitoring and guidance of physiological organ support, and has become the gold standard for the guidance of many invasive procedures.

Competency in Point of Care Ultrasound (POCUS) requires training, experience and tight governance in order to truly benefit patient care. Additionally, it

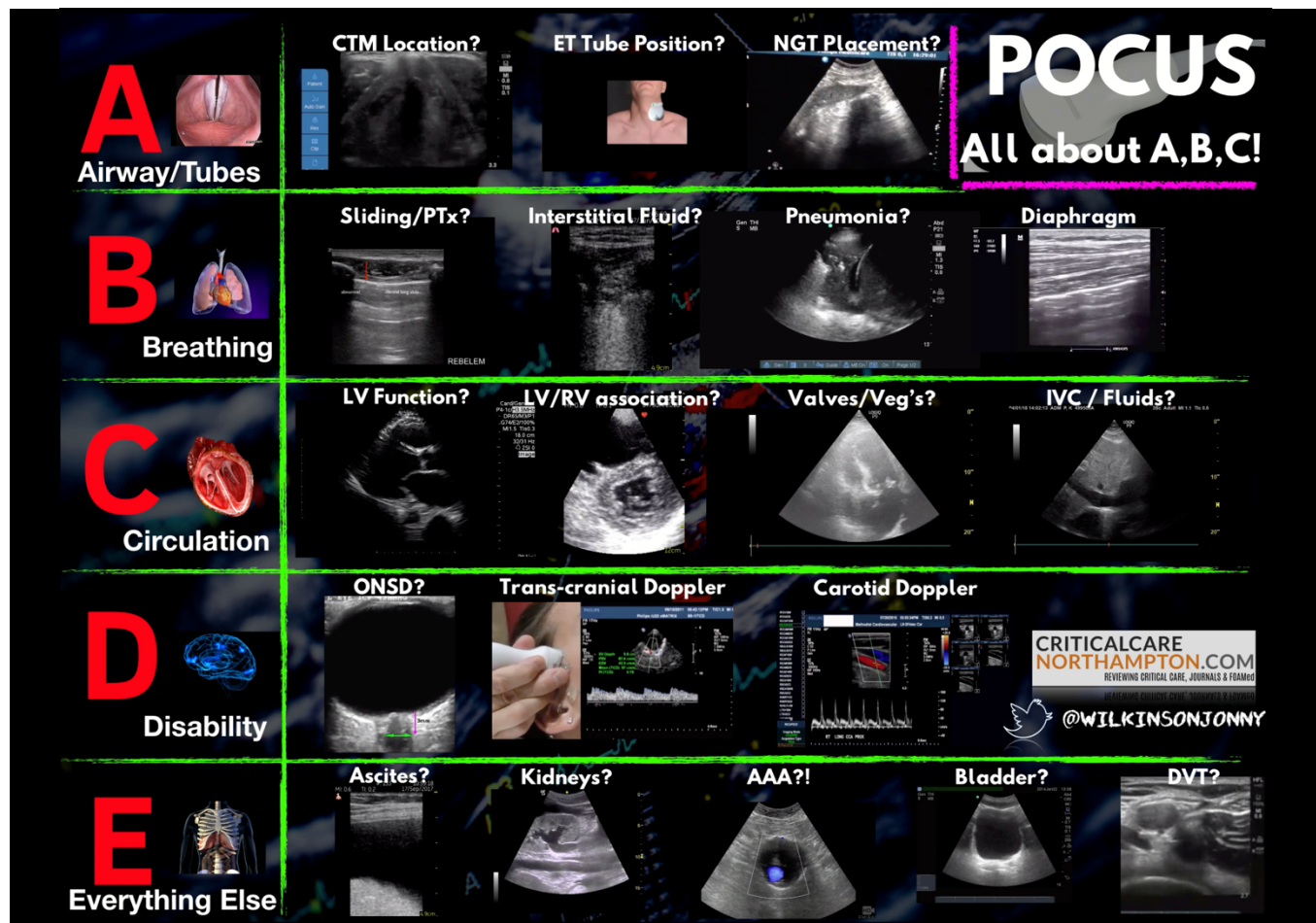

Figure 1. The 'A to E' assessment of a patient using POCUS (Wilkinson J)

- Emergency preparation - identification and marking of the cricothyroid membrane in patients with anticipated difficult airways, prior to definitive intubation. This can offer a vital safety net if emergency front-of-neck access is required, particularly in patients with difficult anatomy.
- Identification of oesophageal intubation - a 'double trachea' sign appears if the oesophagus is inadvertently intubated.

B – BREATHING: Respiratory System

FUSIC Lung

Within ICU practise, lung ultrasound has become a modality with a high yield, devoid of the need for any transport or unnecessary irradiation. Not only does it aid the detection of both acute and chronic pathologies, but it is also a well-established addition

for the guidance of thoracic procedures. This is particularly poignant, as for many years, the ultrasound of air-filled spaces was considered pointless.

Several diagnostic protocols exist to standardise diagnoses, the most famous of which is the Bedside Lung Ultrasound in Emergency (BLUE) protocol (Figure 2) (Lichenstein 2015). There are also more detailed multi-zone scan protocols within lung ultrasound. One such protocol is the 12-lung zone protocol to assess lateral, anterior and posterior pulmonary segments (Gargani et al. 2020).

The BLUE protocol provides the clinician with a sonographic diagnostic pathway, to ascertain why a patient may be hypoxic (Breitkopf et al. 2022). It considers:

- Fluid - pulmonary oedema, pleural effusions
- Thrombus – pulmonary embolism/

DVT

- Pre-existing disease – COPD/asthma exacerbation
- Infection – pneumonia
- Emergencies – pneumothorax

Compared to standard imaging approaches, CT and x-ray respectively, a 9-point lung ultrasound protocol in ventilated patients has been shown to strongly correlate with specific Computerised Tomography (CT) features of respiratory failure. Moreover, it significantly exceeds the sensitivity and specificity profile of chest x-ray in this patient subgroup (Tierney et al. 2020).

Some sonographic features of normal lung include:

- The presence of lung sliding – occurs only when there is no separation between the parietal and visceral pleura (therefore no pneumothorax).
- 'Seashore sign' on M-mode – an arte-

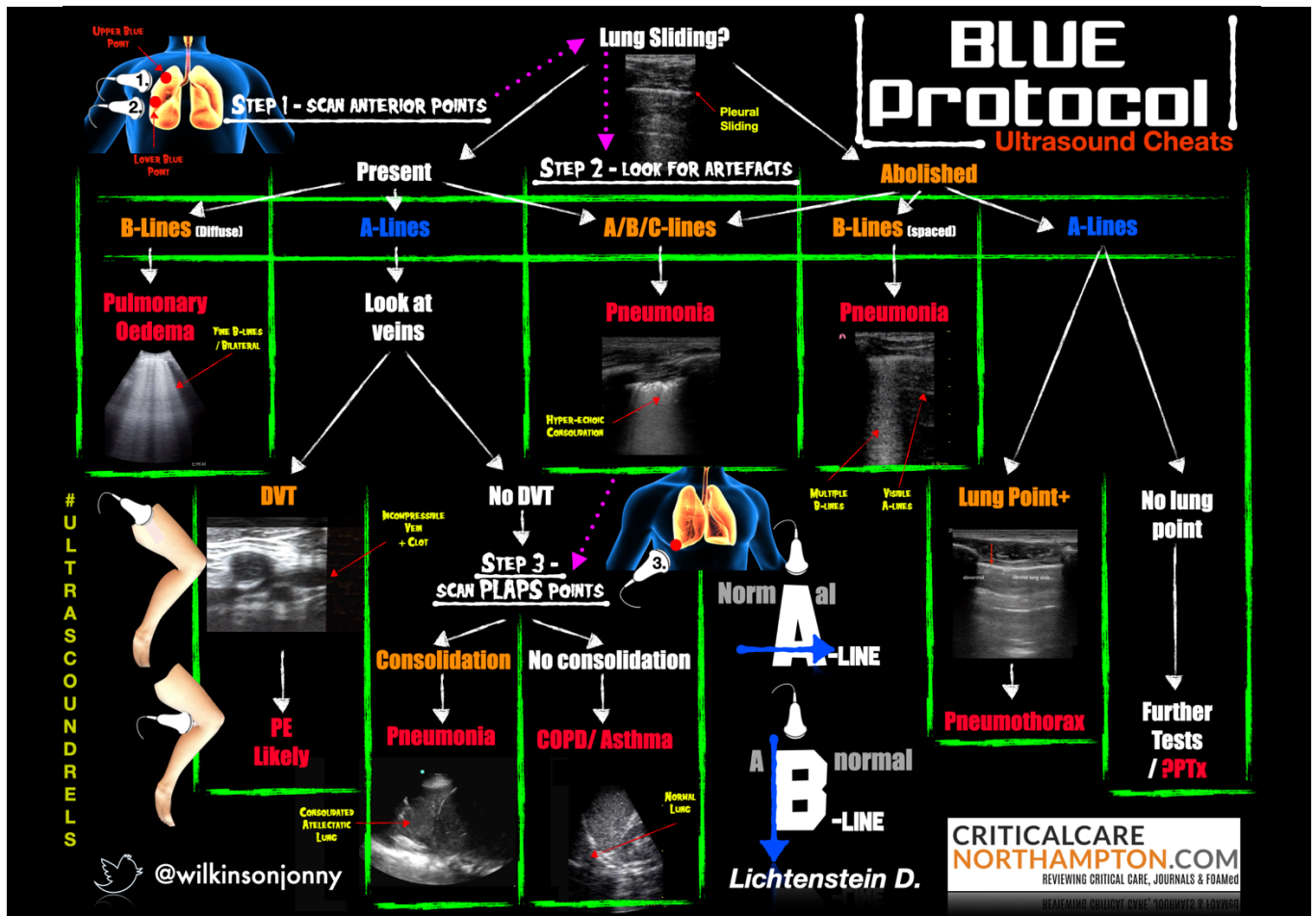


Figure 2. Lichtenstein's BLUE protocol. Reproduced with permission (Wilkinson J)

factual pattern created by sliding pleura (resembling sand, sea and a horizon).

- The presence of horizontal bands called "A-Lines" – appearing as sub-pleural reflections of the pleural layer above (signifying uninterrupted aerated lung below) (Lichtenstein 2005).

In diseased lung and pleura, underlying pathologies produce interruptions to the normal tissue/air interface. Many of these result in either the addition, or absence, of specific ultrasound features compared to that of a normal lung.

Some sonographic (not exhaustive), artefactual appearances at the upper anterior lung points include:

- B-lines – uninterrupted, hyperechoic artefacts that extend from the pleural line, right down the entire length of the US screen. They usually result from the presence of an air fluid interface

(either interstitial or alveolar fluid next to alveolar air), which can be cardiogenic (pulmonary oedema), or non-cardiogenic (pneumonia, contusion, ARDS, fibrosis) (Bouhemad et al. 2007).

- Absence of lung sliding – signifies the pleural layers are either separated or stuck together or absence of respiration. In a pneumothorax there is associated loss of any B-lines and preservation of A-line profile (Breitkopf et al. 2022).
- Stratosphere/barcode sign on M-mode – lack of pleural sliding of the normal M-mode appearance (produces the so called 'sand on the beach' appearance). This is a sign 95.3% sensitive and 91.1% specific for pneumothorax (Lichtenstein 1995).
- Lung point – a horizontally moving interruption to the pleural line, created

by the point where a pneumothorax meets normal lung. This is pathognomonic of pneumothorax.

- Pleural effusion – hypoechoic areas usually seen at the lung bases, surrounding underlying, often compressed, lung. This appears as a very clearly delineated structure, almost similar in appearance to the abdominal organs below the diaphragm. Effusions often cause compression atelectasis until drained. Various formulae exist in order to gauge volumes (Bouhemad et al. 2007). It must be pointed out that many pleural effusions are not apparent on plain film radiography yet are more than clear on ultrasound.
- Consolidated lung – normal air-filled lung cannot be viewed with US as the air reflects the sound waves. Consoli-

dation, on the other hand, transmits ultrasound and appears as hypoechoic areas within the lung tissue, as more sound waves are transmitted by fluid/infected tissue. Air bronchograms may be seen as bright white branching structures. As a result of the infective process, B-lines can appear in the upper zones, often spaced out with normal A-line profiling in between. Subtle areas of consolidation are often far more apparent on ultrasound, than they are visible on a plain chest radiograph.

Such pathology, as described above, may necessitate the need for invasive procedures such as chest drains, or diagnostic/therapeutic pleural aspiration. These procedures carry risk from an anatomical perspective (malposition, pneumothorax, breach of intercostal neurovascular bundles). Pleural effusions are poorly located from a radiographic perspective and represent

the location at the time at which the image was taken, so are subject to alterations in patient positioning. Real time ultrasound represents a safe approach to locating appropriate sites for drainage/aspiration, identifying local structures and ensuring safe needle positioning + guidewire location, as opposed to a landmark technique. (Millington and Koenig 2018).

C – CIRCULATION: Cardiovascular System and Haemodynamics

FUSIC Heart

In the UK, the FUSIC heart module is by far the most popular of the modular accreditations (Intensive Care Society 2021). There are five standard views (Figure 3):

- Parasternal Long Axis (PLAX)
- Parasternal Short Axis (PSAX)
- Apical 4 Chamber (A4c)
- Subcostal 4 chamber
- Inferior Vena Cava (IVC) view

Within those five views are five basic questions:

- Is the left ventricle significantly dilated or impaired?
- Is the right ventricle significantly dilated or impaired?
- Are there features of low venous return?
- Is there a pericardial effusion?
- Is there a pleural effusion?

The above questions are often extremely hard to answer with clinical examination alone, often resulting in best guesswork to align with, or support the clinical picture. Sonography provides a window in to quantify and clearly spot many of the binary answers required to the binary questions.

FUSIC-HD

The new advanced FUSIC-HD module contains 10 more systematic questions, aimed at answering why a patient has

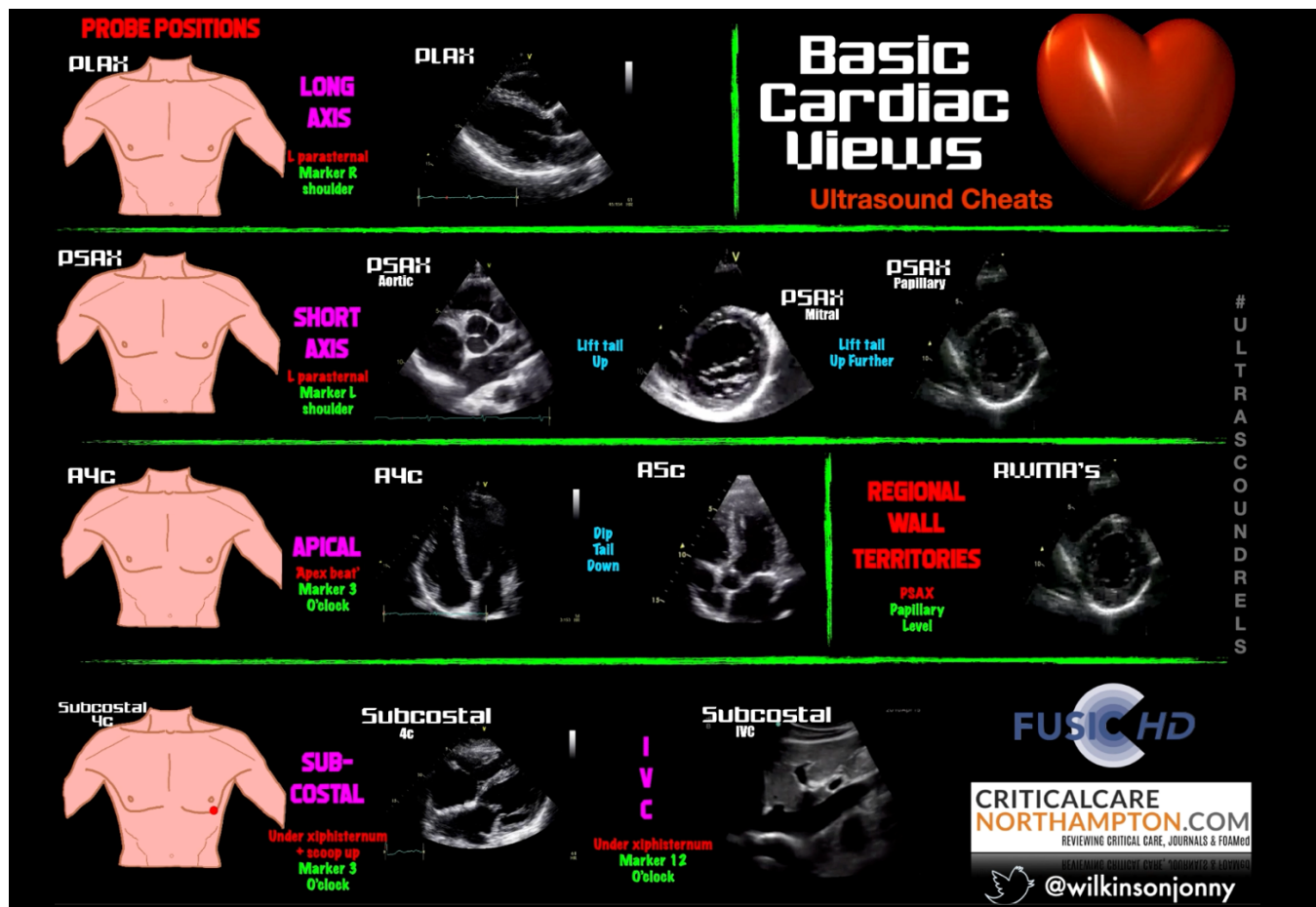


Figure 3. Basic cardiac views (Wilkinson J)

haemodynamic compromise (Miller et al. 2022):

1. Is stroke volume abnormal?
2. Is stroke volume responsive to fluids, vasopressors or inotropes?
3. Is the aorta abnormal?
4. Is the aortic valve, mitral valve or tricuspid severely abnormal?
5. Is there dynamic left ventricular outflow tract obstruction?
6. Is there a regional wall motion abnormality?
7. Is left atrial pressure raised?
8. Is pulmonary artery pressure raised?
9. Are there echocardiographic features of cardiac tamponade?
10. Is there venous congestion?

Using a flow:volume:pressure approach, one can more accurately assess whether a patient will be preload tolerant, or intolerant to IV fluid resuscitation, and/or whether vasopressors are better indicated.

Moreover, the inclusion of many dynamic parameters allows the clinician to monitor the response to any critical treatment decisions made thereon. The final of the questions looks at venous congestion as a cause of organ dysfunction (particularly renal), and/or general deterioration. Sadly, this is a situation sometimes seen in patients where overzealous IV fluid resuscitation. This is especially the case when combined with cardiac impairment. Here, we utilise the venous excess (VExUS) score to de-resuscitate patients, using diuretics or renal filtration, in order to alleviate the effects of congestion.

Cardiac Arrest

An algorithmic approach referred to as Echo Guided Life Support (EGLS) has been suggested (Lancôt et al. 2011), supported by the implementation & training in FEEL (Focused Echocardiography in Emergency

Life Support). This course has been designed as an adjuvant for advanced life support and aims to develop knowledge and skills in obtaining the appropriate and relevant ultrasound windows to identify reversible causes of cardiac arrest, in an ongoing arrest situation (Resuscitation Council 2022).

Examples where POCUS can assist within the 4H's and 4T's of PEA arrest (although not all are included):

- Thromboembolus/Pulmonary Embolus (PE)
 - McConnell's sign (hyperdynamic RV apical cap with poor basal movement)/Reduced tricuspid annular plane systolic excursion (TAPSE)/Right Ventricular (RV) pressure overload/massive Tricuspid Regurgitation (TR)/Deep Vein Thrombus (DVT) found in the lower limbs
- Tamponade
 - Massive pericardial effusion with RV

1. PUMP!

- PLAX** Parasternal Long-Axis View (PLAX)
 - Interventricular septum, RV free wall, Right coronary cusp, Ascending aorta, RV, LA, Pericardium, Descending thoracic aorta, Diastole
 - Pericardium - Tamponade / Effusion?**
- PSAX** Parasternal Short-Axis (PSAX) Views
 - RV cavity, LV cavity, Papillary Muscle Level, Anterior wall, LV cavity, Apical Level, Septal wall, Lateral wall, Inferior wall
 - LV size - Failure / Cardiogenic shock?**
- Apical** Apical 4-Chamber View (A4C)
 - Interventricular septum, LV apex, Septal leaflet, Tricuspid valve, Anterior leaflet, Mitral valve, RA, LA, Descending thoracic aorta, Right lower pulmonary vein, Systole
 - RV size - Failure / PE?**
- Subcost** Subcostal (SC) 4-Chamber View
 - Interventricular septum, Lateral wall of the right ventricle, RV, LV, RA, LA, Anterolateral papillary muscle, Tricuspid valve, Inferior wall, Inferior wall, Posterior leaflet of mitral valve

2. TANK!

- IVC** Collapsible - Shock / PE?
- LUNG** Rib, Pleura, PTx / Oedema / Effusion?
- RUQ** Liver, Kidney, Mirroring
- LUQ** Blood / Free fluid? Spleen, Kidney, Mirroring
- Parasag Abdo.** Bladder, Prostate

3. PIPES!

- Abdo. Aorta** AAA / Rupture / Dissection? IVC, V. Body
- Femoral Vein** SFJ, CFA, CFV
- Popliteal Vein** Compressible - DVT? Pop. V, Pop. A

RUSH Protocol Ultrasound Cheats

CRITICALCARE NORTHAMPTON.COM
REVIEWING CRITICAL CARE, JOURNALS & FOAMed

ULTRASOUND REELS

@wilkinsonjonny

(Wilkinson J)

diastolic collapse/Right Atrial (RA) systolic collapse/plethoric IVC

- Tension pneumothorax
 - Absence of pleural sliding/no lung pulse/lung point/stratospheric M-mode
- Hypoxia
 - Multiple other sonographic indicators within this list/B-lines on lung ultrasound/collapse-atelectasis/severe consolidation
- Hypovolaemia
 - Kissing Left Ventricular walls/collapsing or near absent IVC/Rapid ventricular rate (Flower et al. 2020)

One final area of growth within EGLS is in governing whether cardiac arrest patients are in true Pulseless Electrical Activity (PEA) or pseudo-PEA. Distinguishing between the two relies on POCUS and directs the provider as to the correct ongoing management. The former requires ongoing Advanced Life Support with cardiac massage, whilst the latter may require push-vasopressor therapy over continued cardiac massage. The vasopressor approach to pseudo PEA is supported by an evidence base, though small, with return of circulation rates of 70.4% for those in pseudo-PEA, 20.0% for those in true PEA, and 23.5% for those in asystole (Flato et al. 2015).

Protocols

As well as FUSIC-HD, there are other highly useful protocols to aid recognition of the causes of undifferentiated shock. Many may avoid the requirement for further CT imaging and indeed may identify a clear cause where immediate surgical intervention is the priority. One such example is the Rapid Ultrasound in Shock (RUSH) protocol, which uses a “Pump, Pipes and Tank” approach (Figure 4) (Seif et al. 2012):

- Pump = Heart
- Pericardial Effusion, LV contractility & RV dilatation
- Tank = volume loss/status
- Fullness - IVC size & collapsibility
- Leaks - presence of haemorrhage identified during FAST & thoracic ultrasound
- Compromise - Pneumothorax & Rupture. Aortic Aneurysm & Dissection
- Pipes = DVT

This approach has been shown to reduce many diagnostic uncertainties governing the shock state (Shokoohi et al. 2015).

D – DISABILITY: CNS (Central Nervous System)

FUSIC neuro, forthcoming

Given the bony anatomy of the skull, there are limited avenues for the application of POCUS to image the central nervous system. Although CT imaging remains the most accepted method of detecting signs of raised ICP, midline shift, space occupying lesions & cerebrovascular catastrophes, ultrasound does have a role in certain scenarios. The use of a transorbital window allows the user to assess pupillary light reflexes and potentially monitor changes in intracranial pressure through the serial measurement of optic nerve sheath diameter as a surrogate marker, in the absence of orbital trauma or haemorrhage (Bhatt et al. 2020).

Utilising a trans-temporal window, one can exploit the relatively thin aspect of the temporal bone to perform transcranial ultrasound. With the use of Doppler flow, the transcranial approach can then be manipulated as a safe, rapid and non-invasive method to further assess and monitor ICP, cerebral blood flow in the context of brain death and to diagnosis and guide management of cerebral artery vasospasm (Lau and Arntfield 2017).

More recent literature supports this, with transcranial Doppler providing a key role in the screening and monitoring of middle cerebral artery vasospasm, with 89-98% sensitivity in the critical care patient (Dinsmore et al. 2022). The authors also describe a method of non-invasive ICP monitoring, through the serial trend measurement of optic nerve sheath diameter, and the detection of midline shift via trending of the calculation of the difference in measurement from ipsilateral temporal bone to the 3rd ventricle on both sides. Once again, it is the trend in these values supported by clinical information that helps guide treatment, rather than a one-off value. There are key limitations such as artefact interference due to bone, and no real consensus on upper limit values.

Overall, these approaches require a

high level of competence, but highlight the use of brain ultrasound as an alternative imaging technique for the diagnosis and management of certain neurological pathologies on intensive care.

E - EVERYTHING ELSE

Abdominal Ultrasound

FUSIC Abdomen

Under certain circumstances, the use of CT imaging is more accurate than ultrasound in the context of abdominal pain (Lameris et al. 2009). In the critically ill trauma patient, the abdominal focused abdominal sonography in trauma (FAST) protocol has a high specificity (99.5%) and sensitivity (94.8%) as a screening tool for haemoperitoneum and abdominal free fluid. However, it is unable to determine the exact source of extravasation (Basnet et al. 2020). In the context of a positive FAST scan with significant cardiovascular compromise (e.g. aneurysmal rupture), there is an indication to proceed to immediate surgical intervention without the delays of further imaging, demonstrating the rapid use of ultrasound in interventional management in the abdominal setting. However, a negative FAST scan does not equate to complete rule out of any significant pathology in the unstable patient. There is more evidence in support of performing serial FAST scans to improve diagnostic yield (Figure 5) (Zieneldin et al. 2017).

Outside of the FAST protocol, POCUS can be used for a variety of other roles (Balmert et al. 2017):

- Hepatobiliary system
 - Assessment of liver architecture and flow patterns
 - Assessment for gallstones and ductal abnormalities
 - The presence of ascites and real-time guidance of paracentesis catheters/needles
- Vascular system
 - Assessment of aortic diameter for aortic aneurysm
- Genito-urinary system
 - Assessment of the correct placement of urinary catheters + bladder volume assessment.
 - Assessment of hydronephrosis

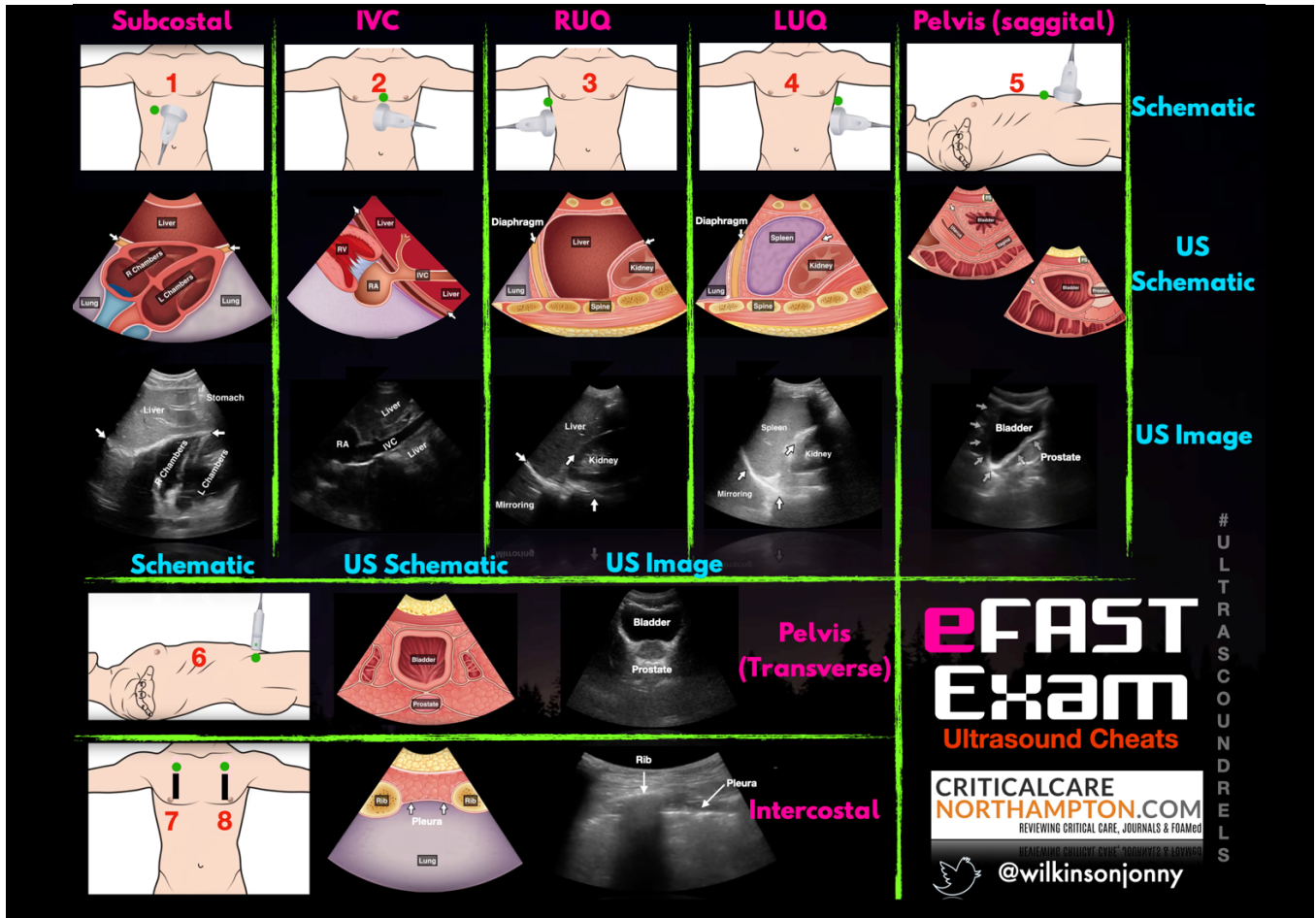


Figure 5. Extended FAST (eFAST) protocol (Wilkinson J) – FAST scan + incorporation of upper anterior chest wall views looking for pneumothorax

- Interrogation of the renal resistive index (RRI) as an indicator of impending acute kidney injury.
- Assessment for the presence of renal calculi
- Gastric and intestinal
 - Identification of gastric residual volume
 - Correct placement of a nasogastric tubes
 - Assessment of small bowel obstruction/perforation (Kameda and Taniguchi 2016)

Invasive Procedures

Ultrasound can assist the safe placement of various indwelling catheters (Figure 6). The classic example is the direct visualisation and utilisation of static and dynamic guidance for the siting of central venous catheters/dialysis catheters. One can see the vessel, highlighting it with colour and

pulsed wave Doppler to gauge whether arterial or venous. The needle can then be directed in plane or out-of-plane into the vessel and subsequently, the wire and catheter can be visualised as they pass into the vessel guiding correct position prior to dilatation, avoiding misplacement. POCUS can even inform whether the catheter is safe to use, without the need for any accompanying plain radiographs, and can rapidly identify any potential complications such as pneumothorax or haemorrhage (Saugel 2017).

Ultrasound can also guide paracentesis of ascites, in particular, highlighting abdominal wall vessels and negating the risk of penetration in patients with deranged liver function/clotting disorders. The same goes for thoracocentesis, with the recommendations that ultrasound should be used over anatomical landmark techniques.

DVT

FUSIC DVT

Ultrasound provides excellent resolution of vascular structures and is therefore a useful tool in the detection of deep vein thromboses, with a structured training and assessment programme as part of FUSIC (Intensive Care Society, 2021). Basic 3-point compression of the great veins from the sapheno-femoral junction, down over the common femoral vein mid-thigh, to the popliteal vein behind the knee, provides a high sensitivity to rule in a DVT between these points. Almost all DVT's resulting in a PE arise from above the knee, therefore these 3 points are an adequate series in isolation. The addition of colour flow and pulsed wave Doppler to basic 2D ultrasound imaging, upgrades the series to duplex and triplex phase accordingly.

In the context of pulmonary embolism,

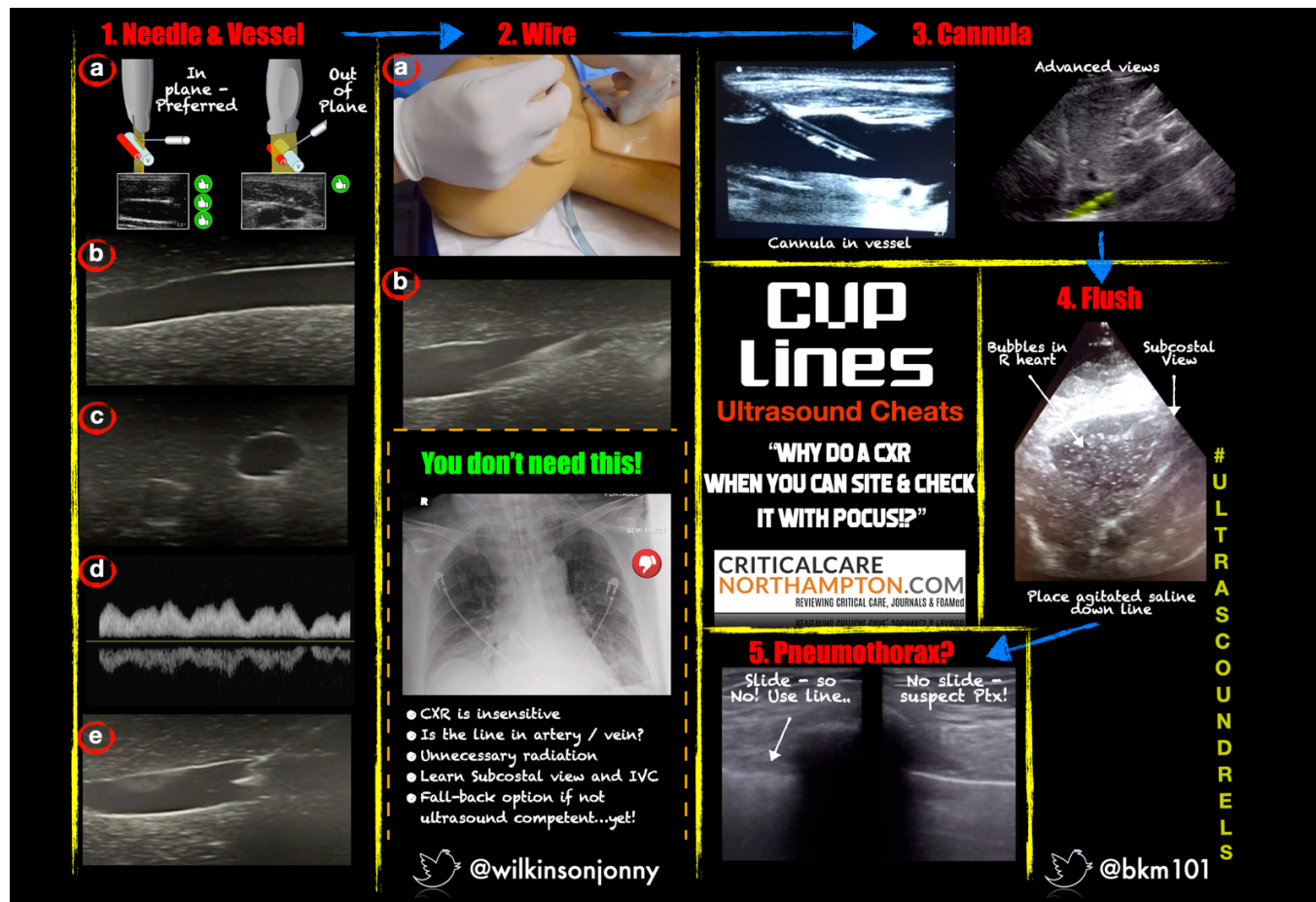


Figure 6. POCUS protocol for safe insertion and checking of an indwelling venous catheter (Wilkinson J)

a multi-organ POCUS approach is needed to select suitable patients for further CT imaging. In resource poor settings, along with the clinical history and examination, heart and lung ultrasound may be the only imaging modality available. While right ventricular strain suggests that a PE is more likely, this finding is non-specific and other potential causes must also be considered (Lieveld et al. 2022). However, the absence of RV strain in a patient with haemodynamic instability means that PE is unlikely to be the cause. Further evidence is required to fully compare both modalities to determine which is the best diagnostic tool (Cao et al. 2022). Nevertheless, clear ultrasound findings in the presence of a severely unstable patient, with a suggestive

clinical history, may assist in the decision-making process for thrombolysis in the absence of 'higher' imaging (Marti et al. 2015).

Conclusion

Overall, point of care ultrasound remains a critical tool in the assessment, diagnosis, and management of pathology in the critically unwell patient. With much improved access to modern, ever more portable ultrasound equipment, POCUS has become an essential adjunct for practitioners both within the critical care unit and outside on the wards, or in the emergency department. Multiple accreditation programmes are available, many of which arm the clinician with an extremely solid base in whole body,

diagnostic ultrasound. It is the authors opinion that POCUS should be introduced early on in the training schemes of both medical and non-medical practitioners. With good quality training users will be able to embrace its benefits and limitations in order to make many rapid critical treatment decisions at the bedside of the sickest patients, often avoiding the need to transport them to places with a lower safety profile for further imaging.

Conflict of Interest

Jonny Wilkinson, Marcus Peck and Ashley Miller receive honoraria from GE Healthcare. MP and AM are co-chairs of the FUSIC committee. JW is a member of the FUSIC committee. ■

References

For full references, please email editorial@icu-management.org or visit <https://jii.hm/1iny>

INTENSIVE CARE | EMERGENCY MEDICINE | ANAESTHESIOLOGY

icu-management.org  [@ICU_Management](https://twitter.com/ICU_Management)

ICU

MANAGEMENT & PRACTICE

